Caso nº 5

Hospital General Universitario de Alicante

Cristina Alenda

Reunión territorial de la SEAP

Castellón, 21 junio 2002

Resumen historia clínica

- Mujer de 14 años con adenopatías en región inguinal derecha y laterocervicales.
  - Biopsia ganglio cervical

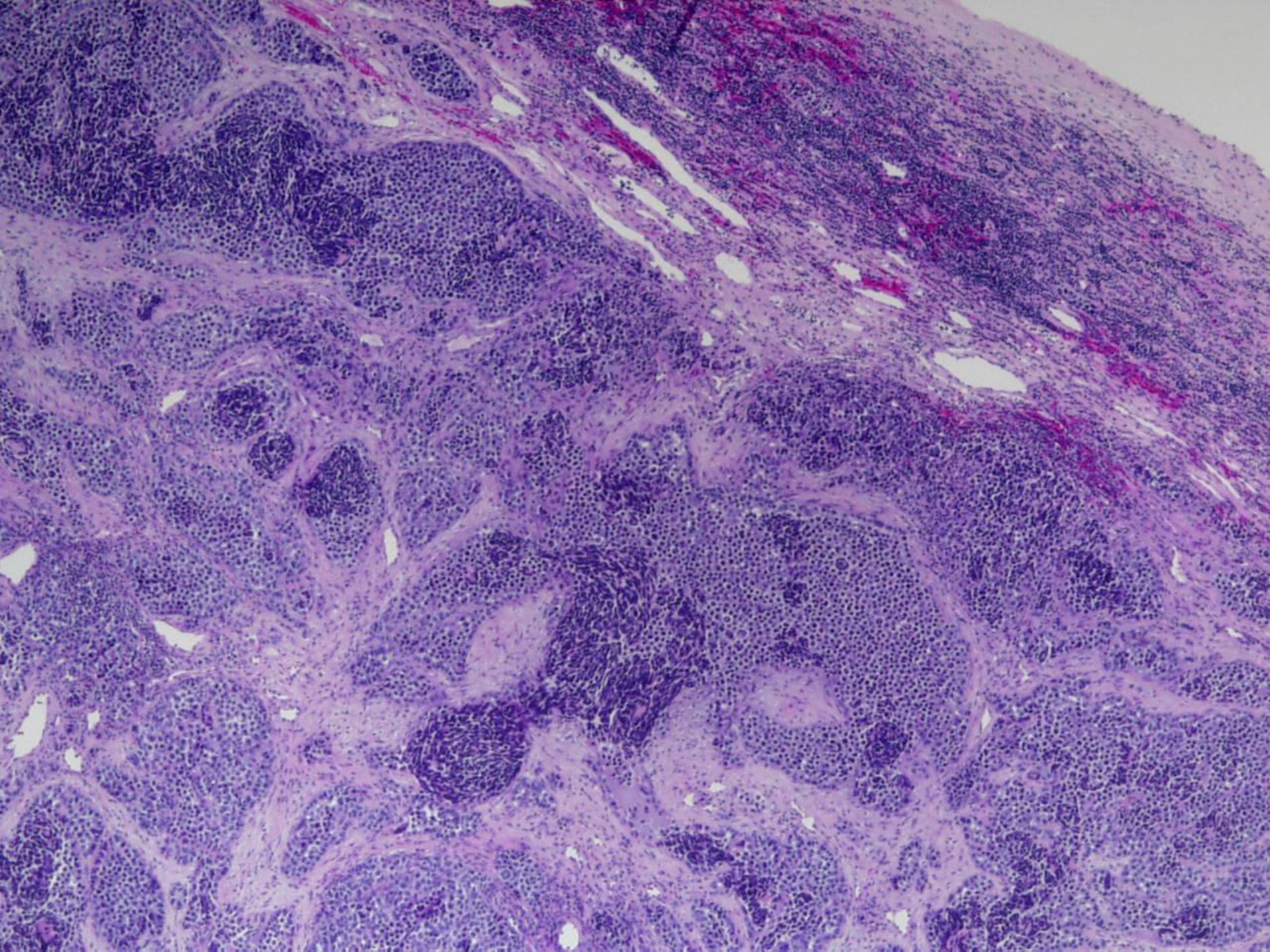

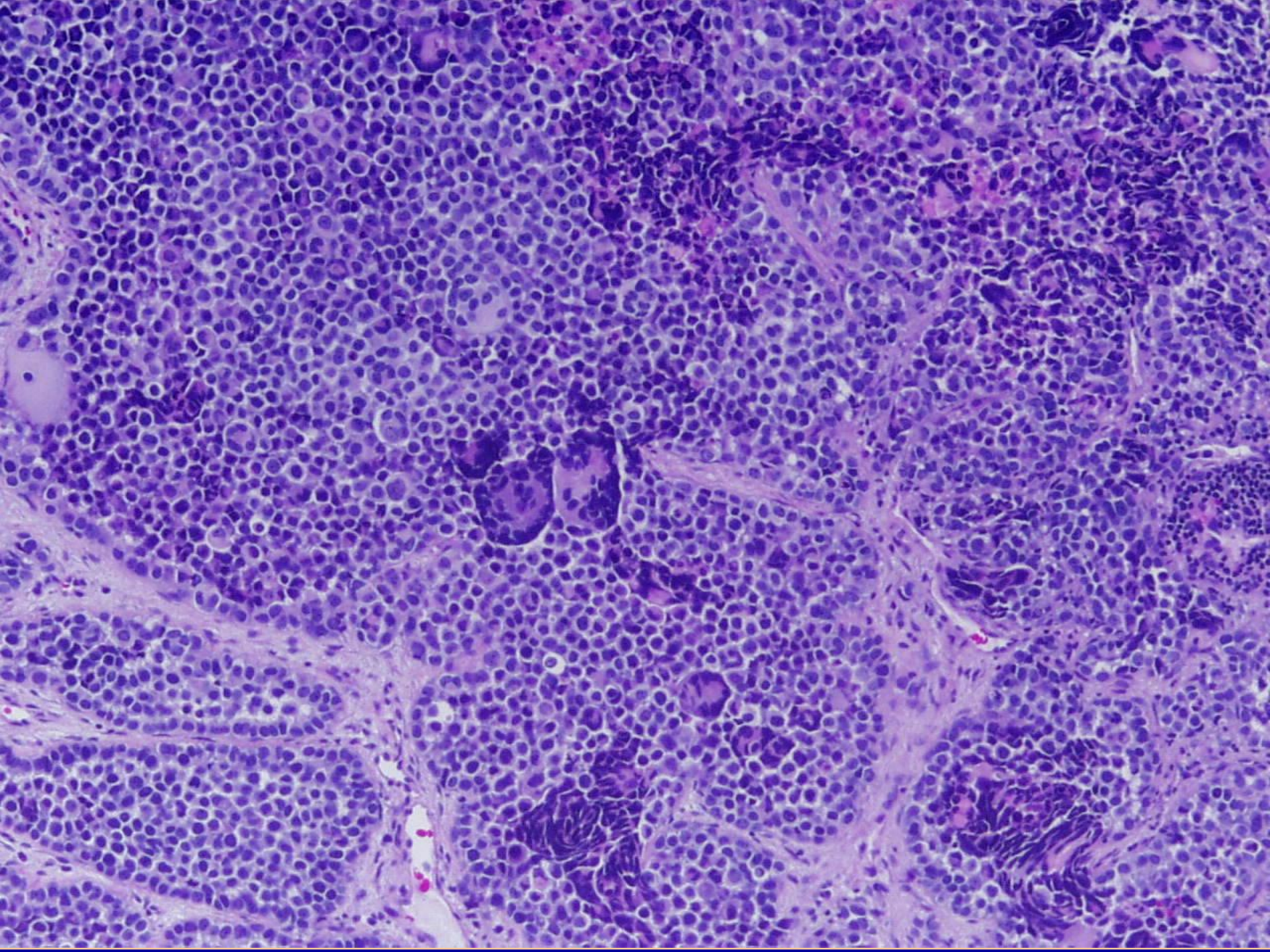

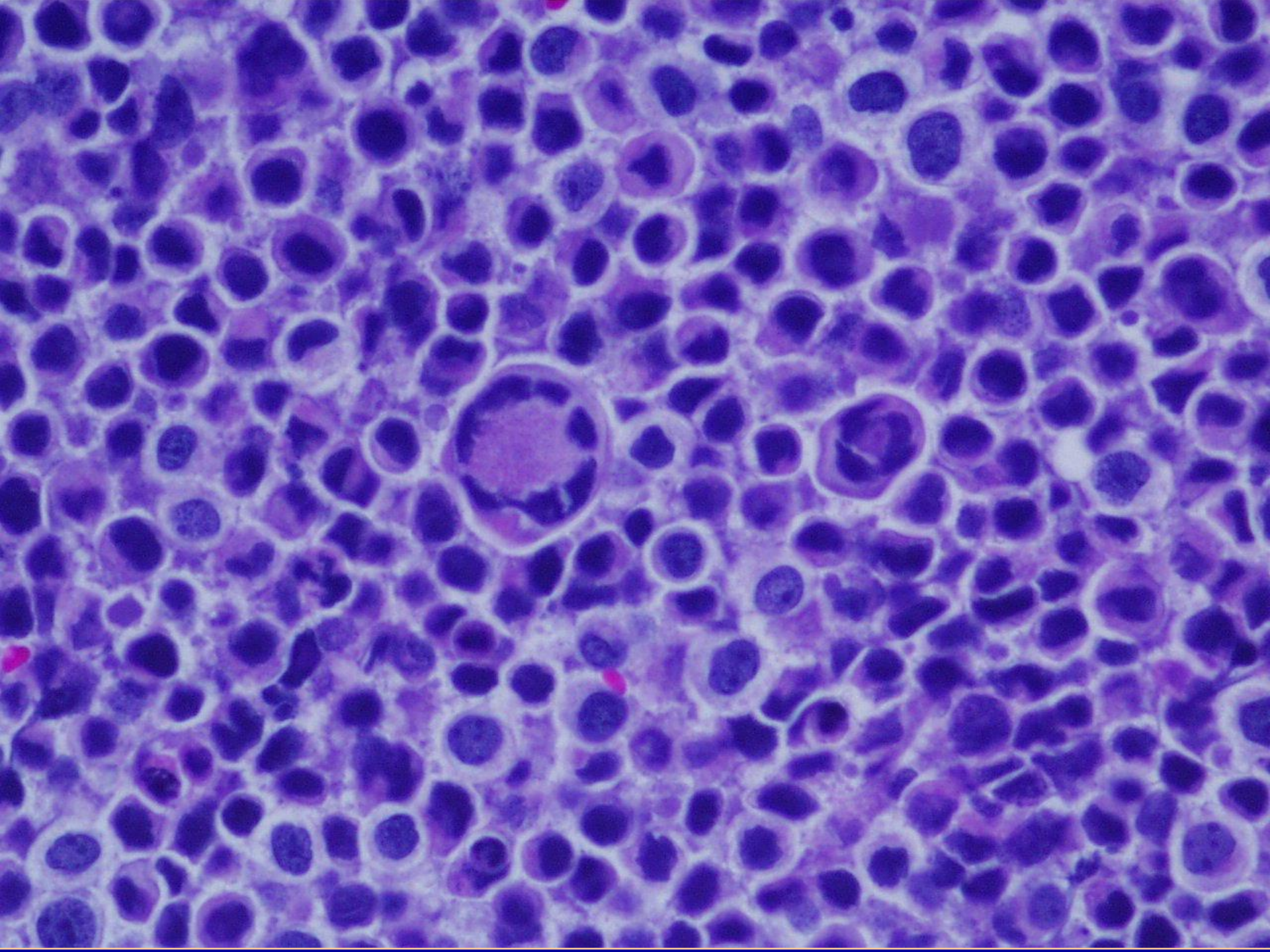

Rabdomiosarcoma alveolar

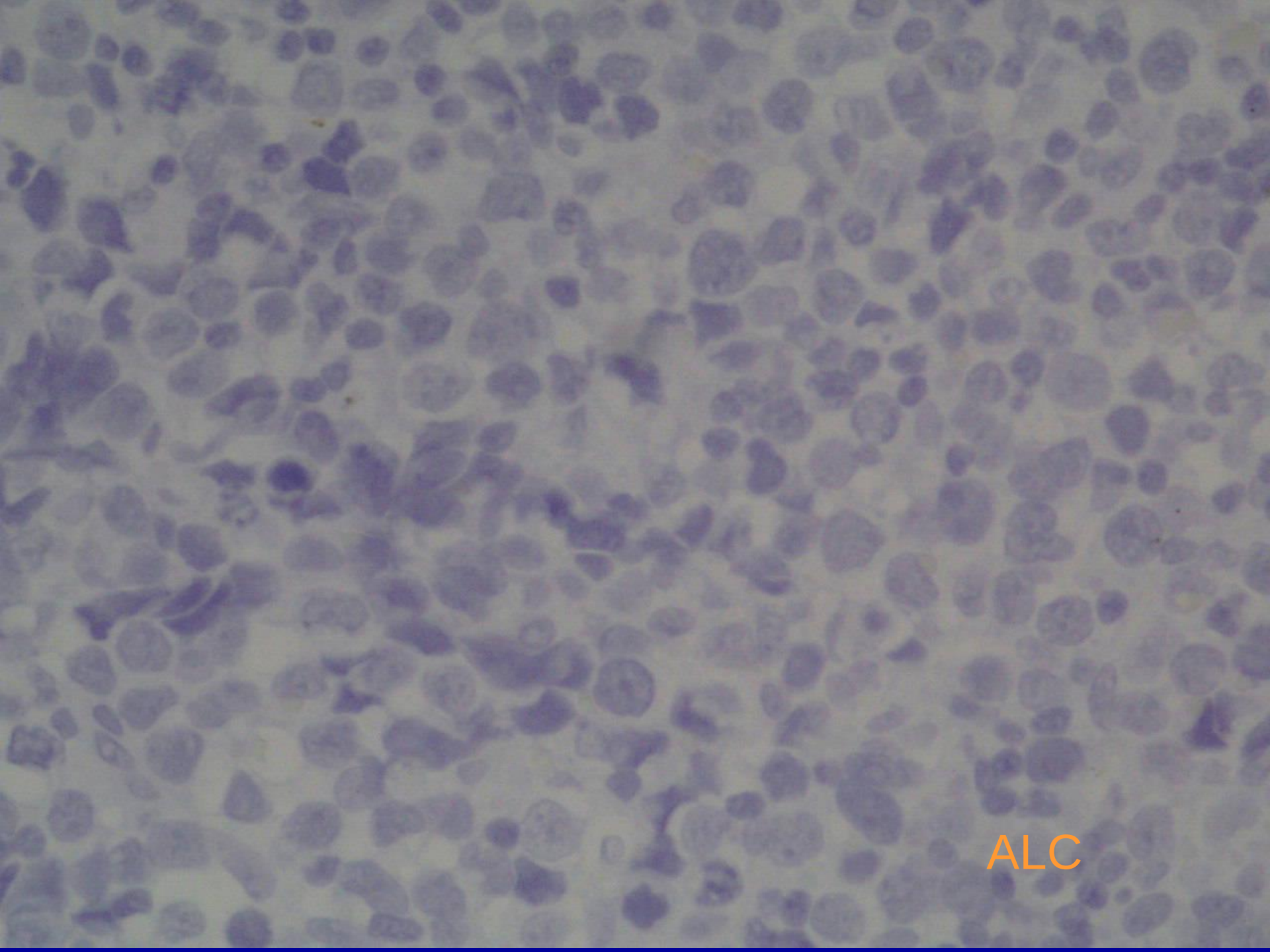
ALC

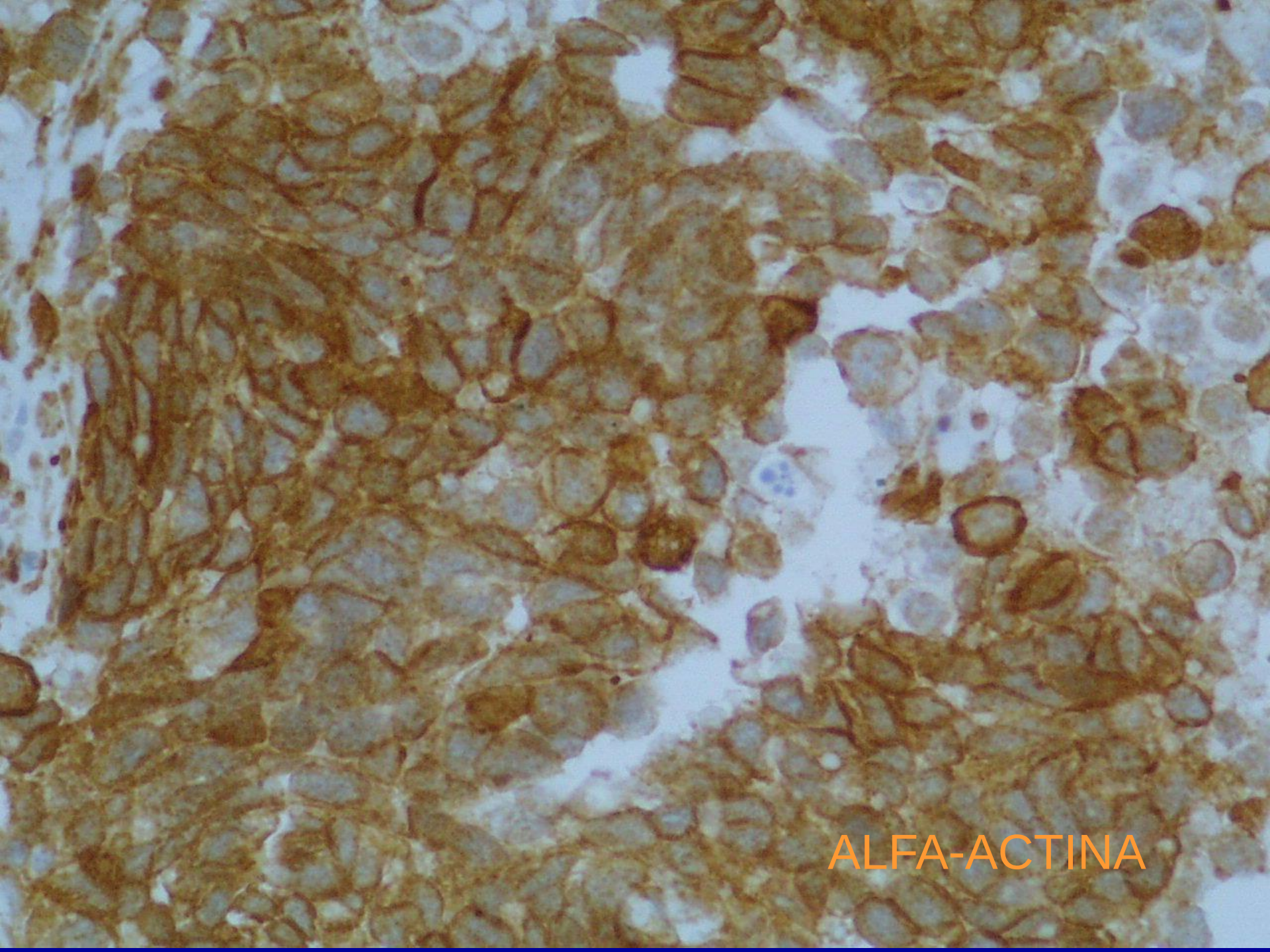
ALFA-ACTINA

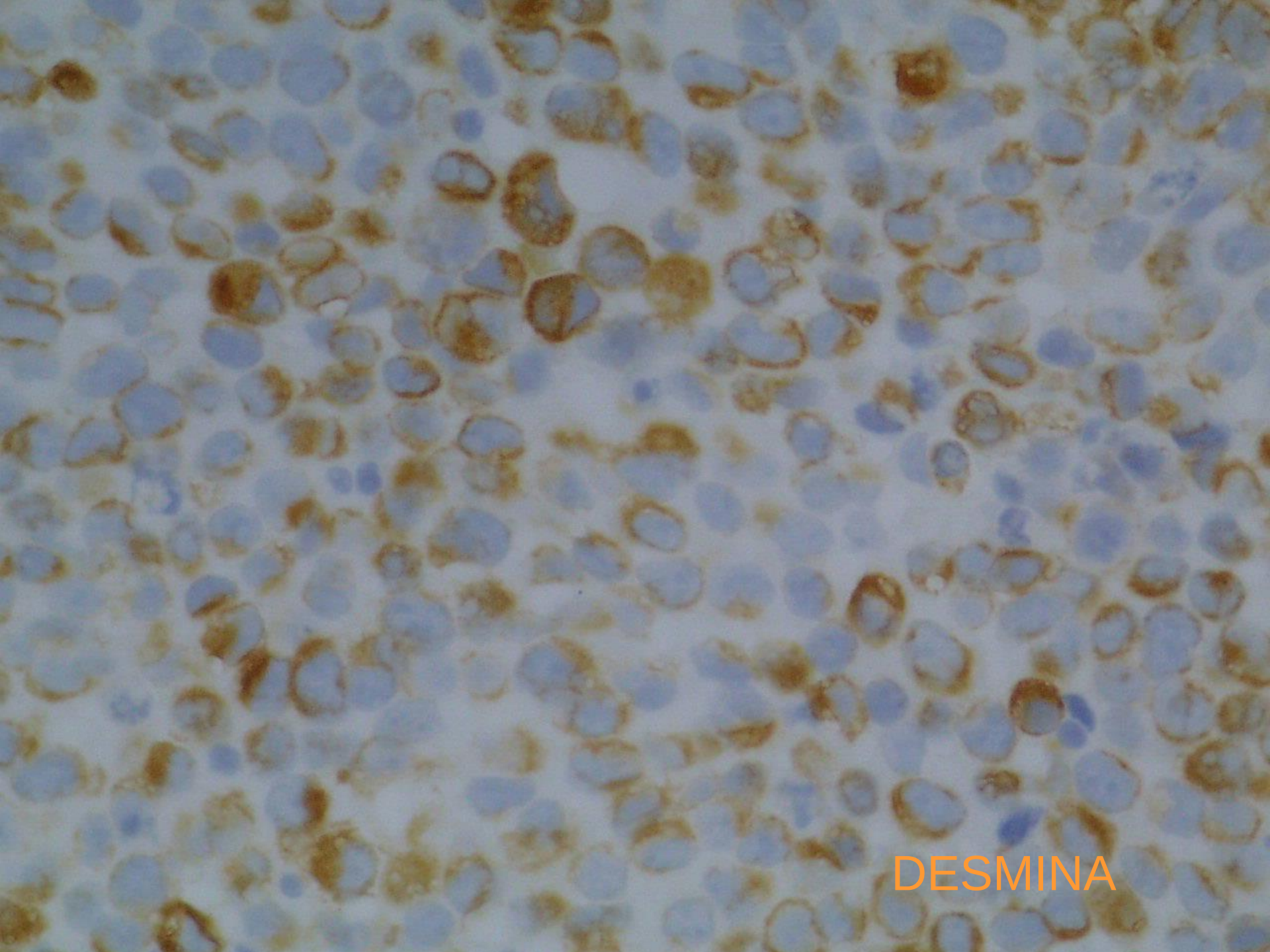
DESMINA

Radiología

- TAC: masa paraanal derecha y adenopatías inguinales, ilíacas, paratraqueales y cervicales.
- RMN: afectación de estructuras musculares de pelvis. Masa de 5 cm en lado derecho de esfínter anal externo. Adenopatías retroperitoneales.

Sc 5
TSE/M
SL 15
H
P
10 cm

Sc 9
TSE/M
SL 15
H
L
cm
AP 56 post

Evolución

- Abril 2000 — Inicio tratamiento citostático
- Enero 2001 — Fin tratamiento
- Octubre 2001 — Masa en mama
  RMN y TAC: tumoración bilateral de mama

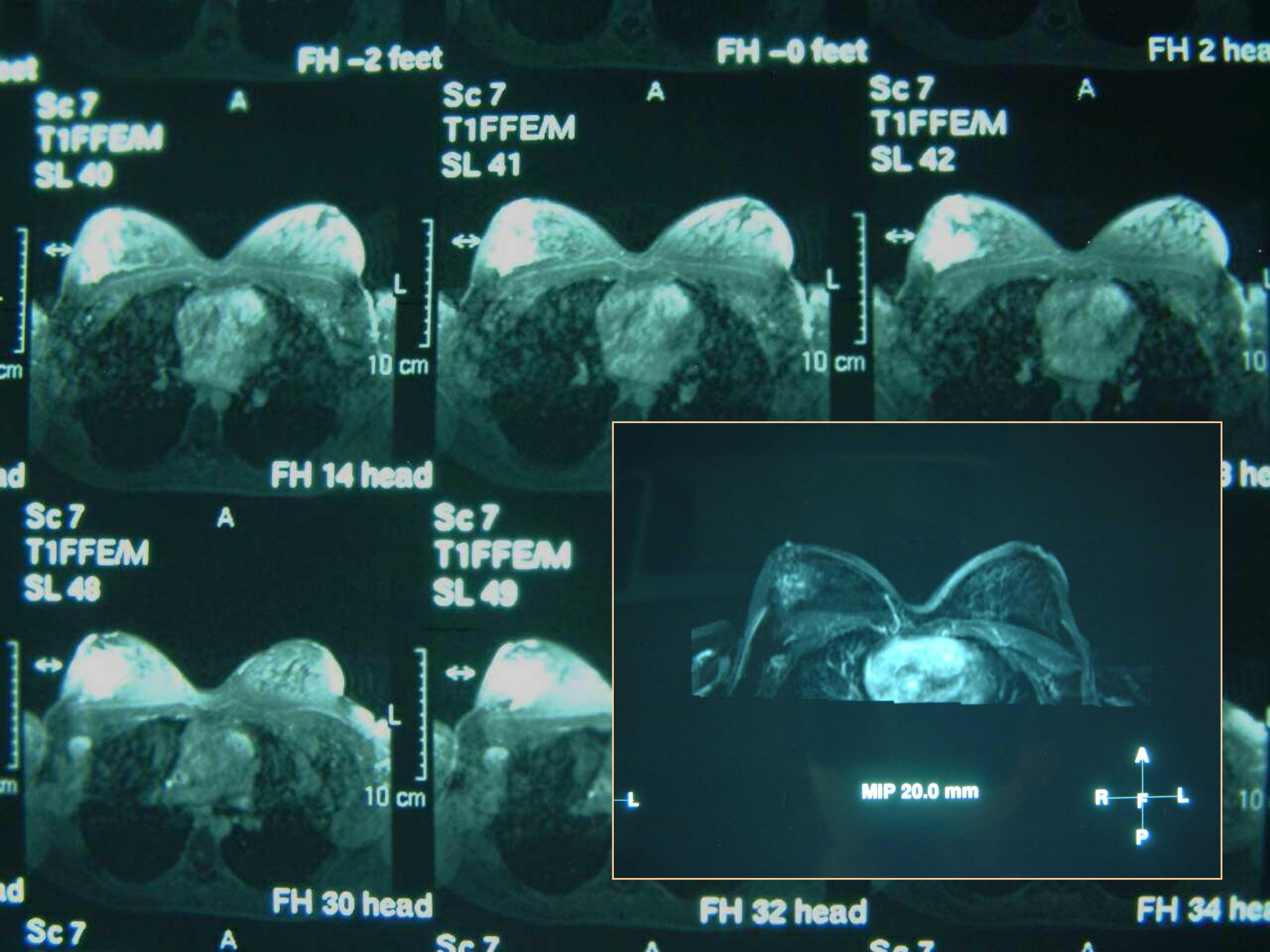
FH -2 feet
FH -0 feet
FH 2 hea
Sc 7
T1FFE/M
SL 40
A
Sc 7
T1FFE/M
SL 41
A
Sc 7
T1FFE/M
SL 42
A
L
10 cm
FH 14 head
Sc 7
T1FFE/M
SL 48
A
Sc 7
T1FFE/M
SL 49
L
10 cm
FH 30 head
FH 32 head
FH 34 hea
MIP 20.0 mm
A
R
F
L
P
L

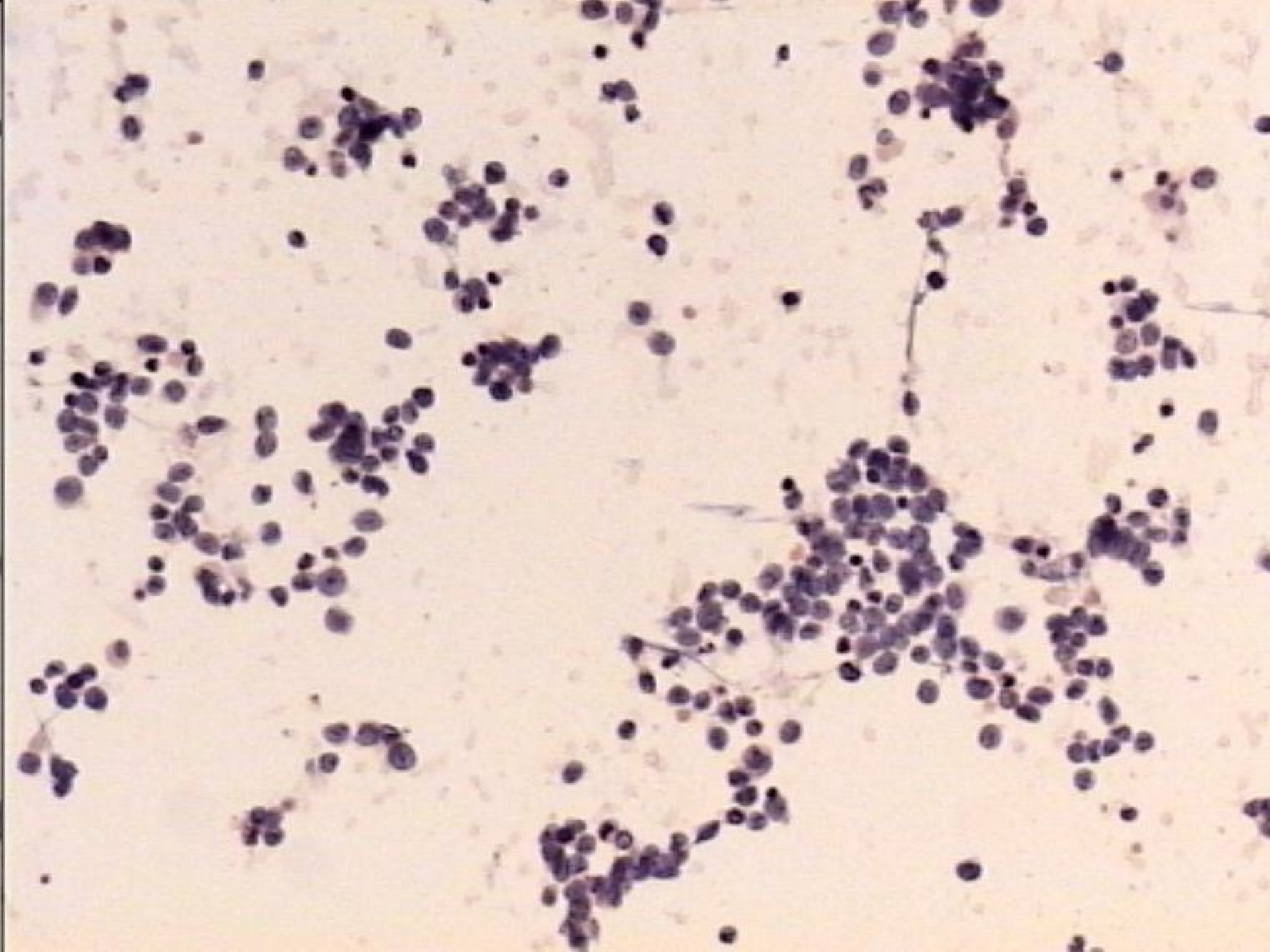

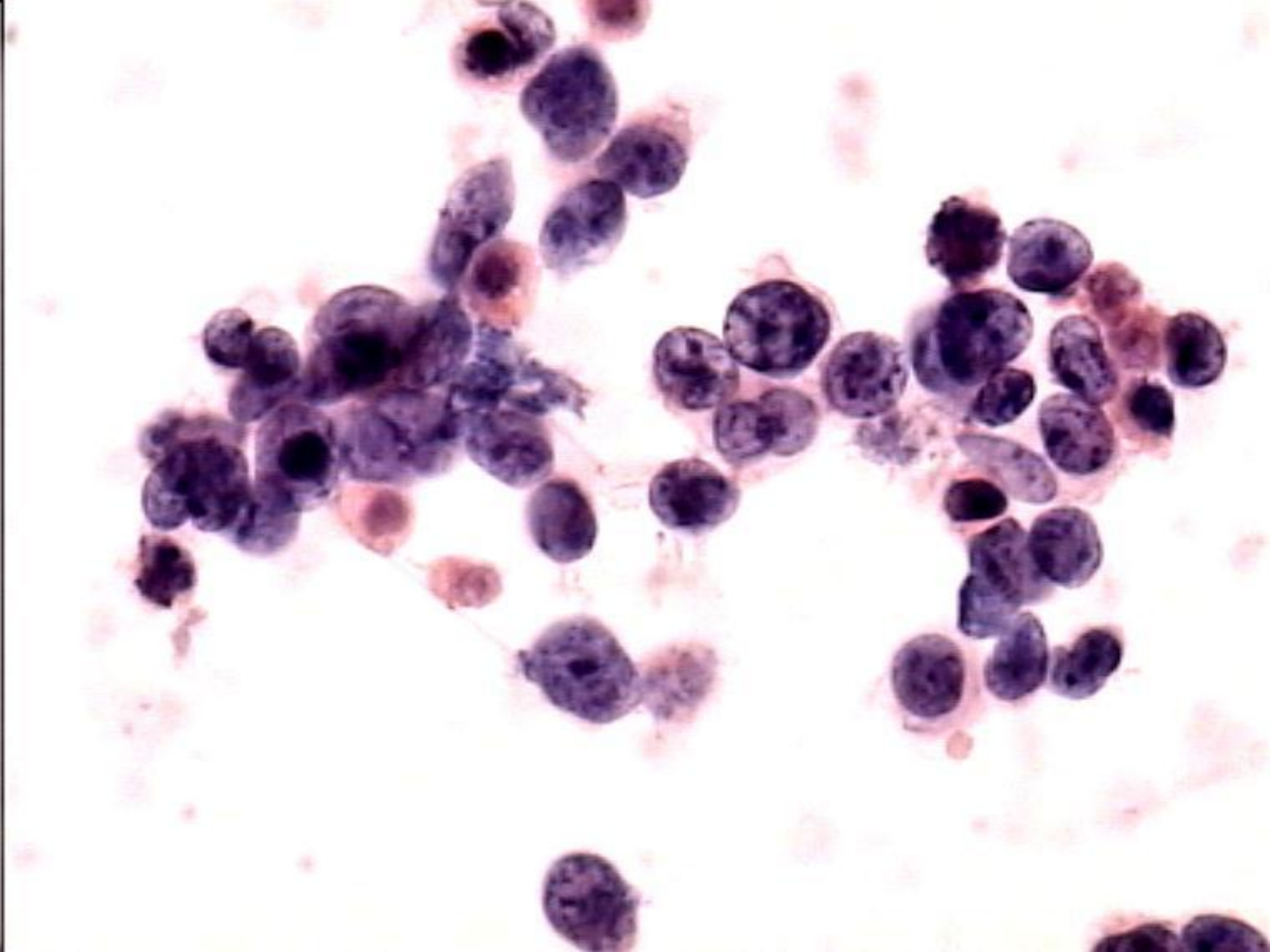

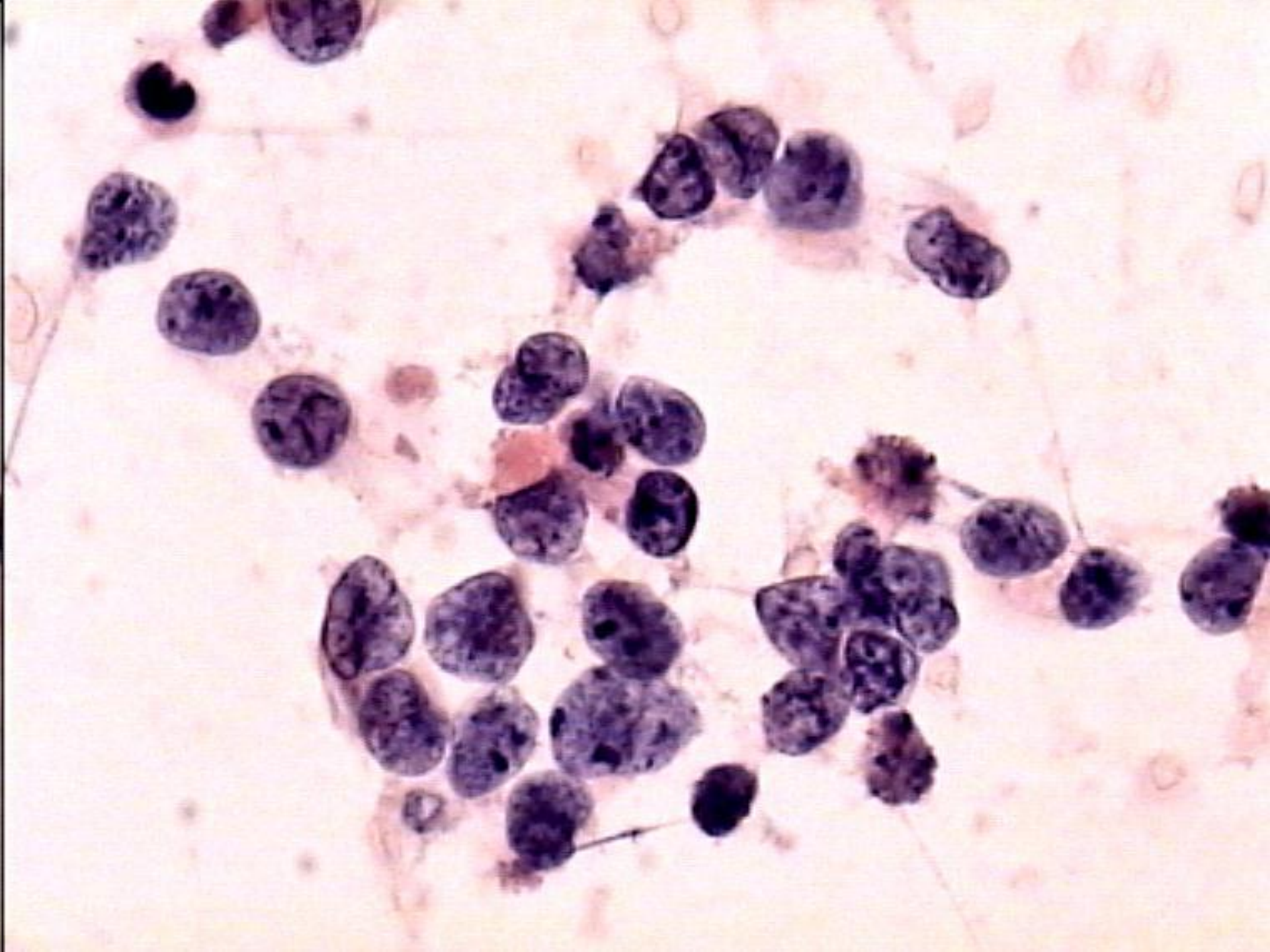

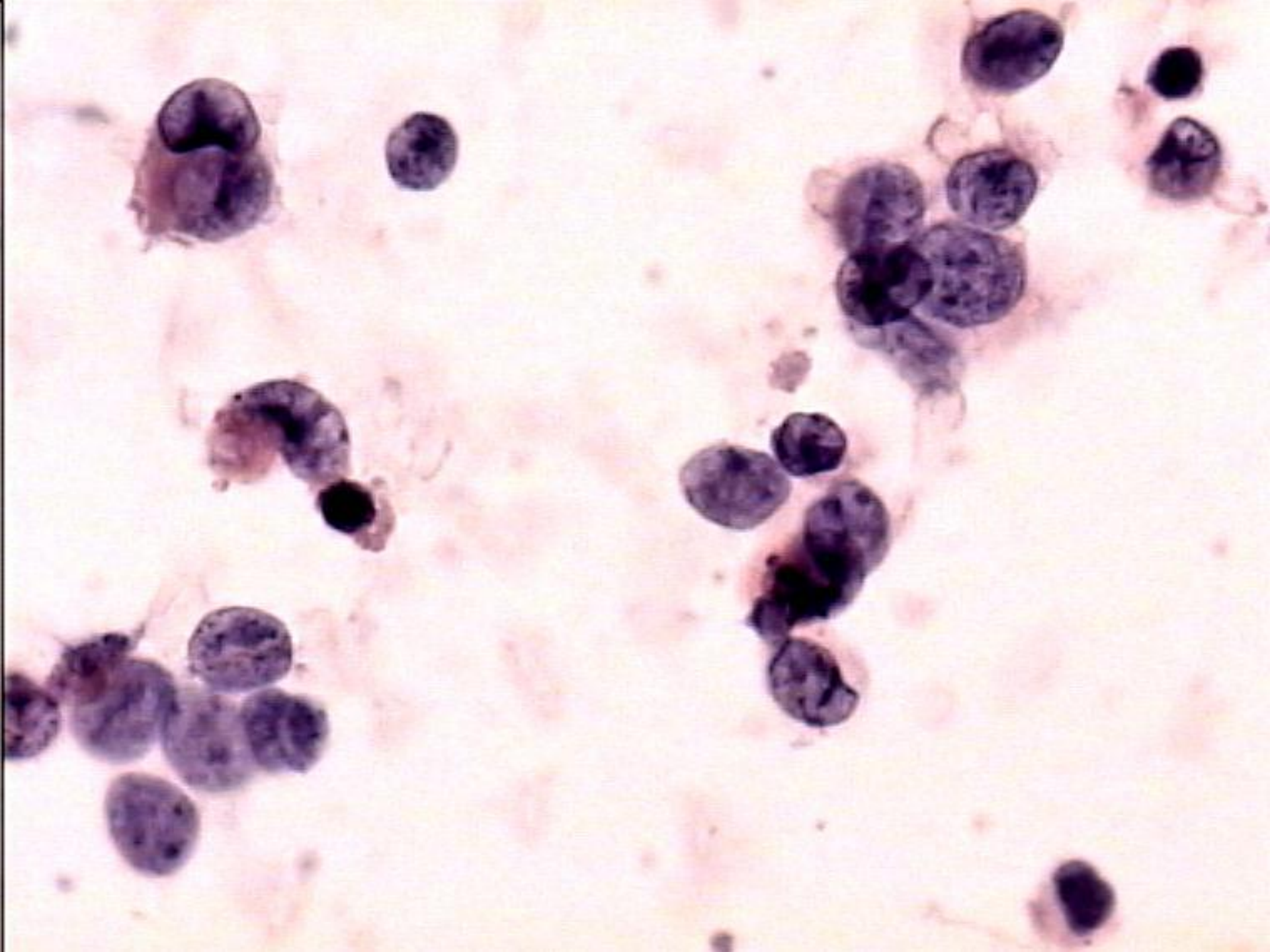

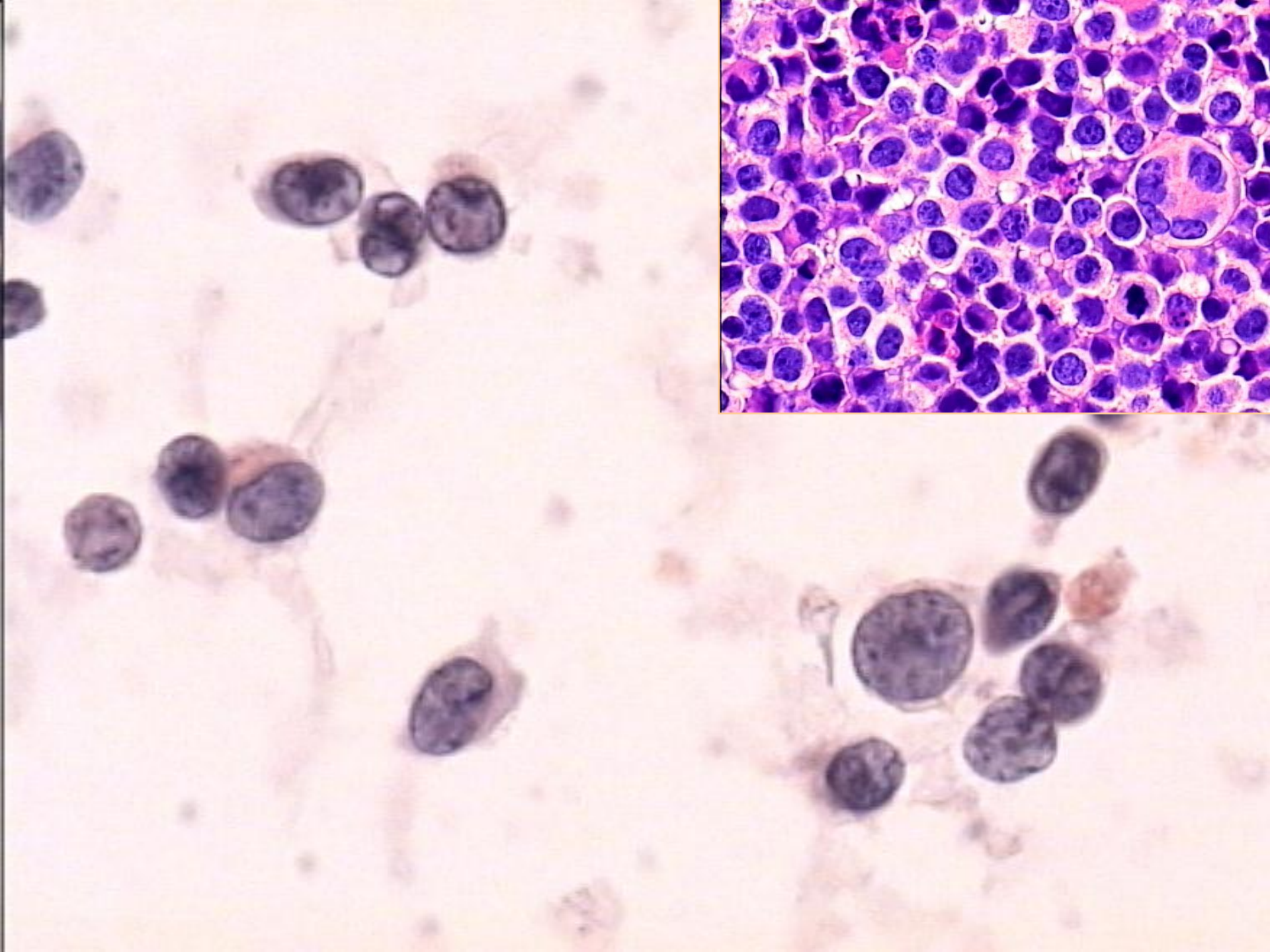

Evolución

- Octubre 2001 Quimioterapia con Topotecán
- Marzo 2002 Reducción del tamaño de los tumores.
  Mastectomía bilateral con linfadenectomía axilar y reconstrucción inmediata

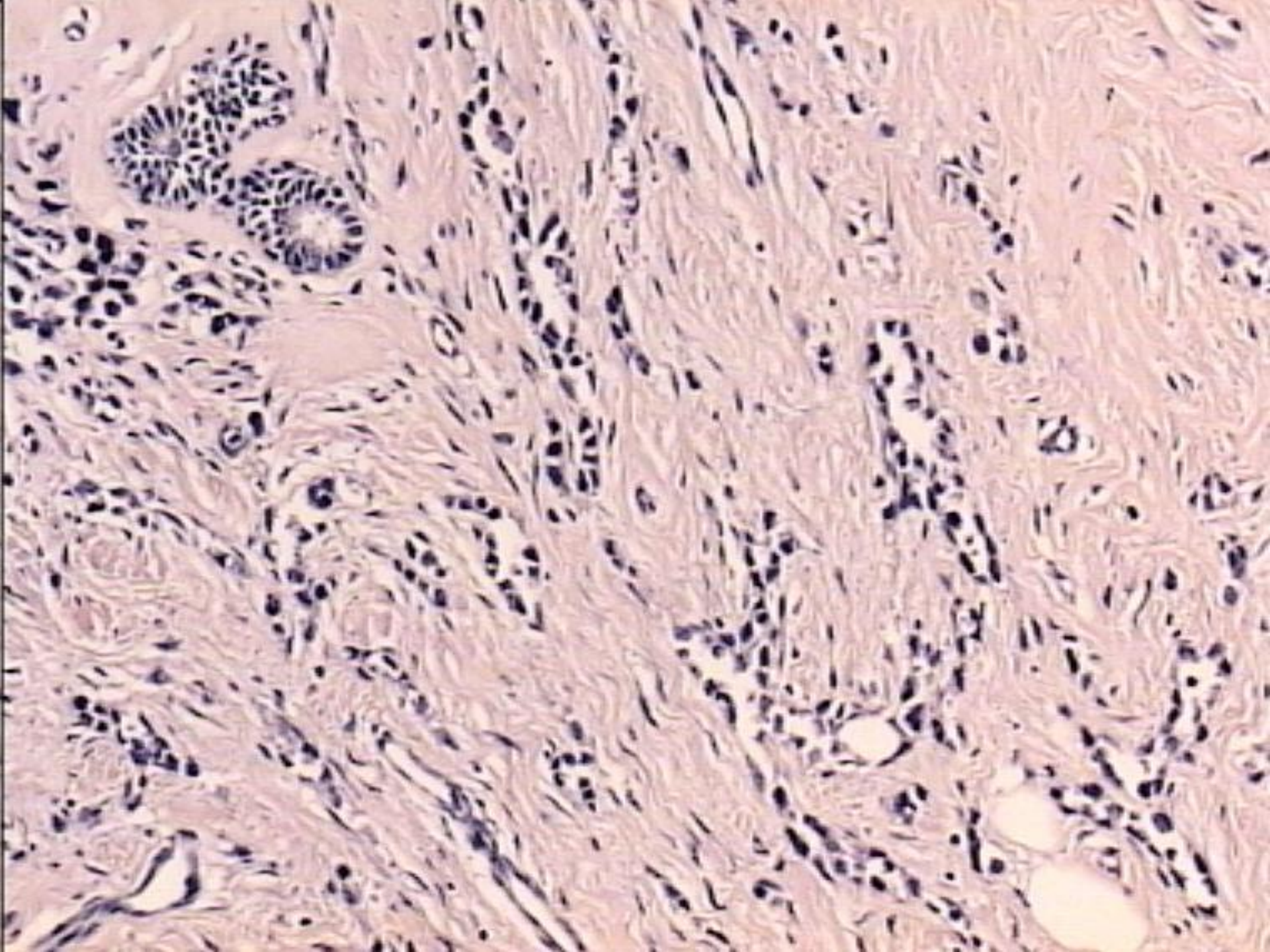

Rabdomiosarcoma metastásico

- Metástasis de rabdomiosarcoma: pulmón (60%), ganglios linfáticos (50%), hueso (40%), SNC (25%), hígado (25%).
- Los tumores mamarios malignos más frecuentes en niños son metastásicos.
  - Rabdomiosarcoma alveolar
  - Linfoma