HOSPITAL SAN JAIME. TORREVIEJA. ALICANTE

PATOLOGIA

Dra Chulia, Dr. Fernández, Dr. Forteza

Hª CLÍNICA

- Paciente de 30 años.
- Tumoración inguinal derecha (10cm)
- Sospecha de metástasis pulmonares
- Exeresis en la CUN (Noviembre de 2000)
- Bloque de parafina----diágnostico de sarcoma fusocelular----probable sarcoma sinovial----pendiente de estudio molecular.

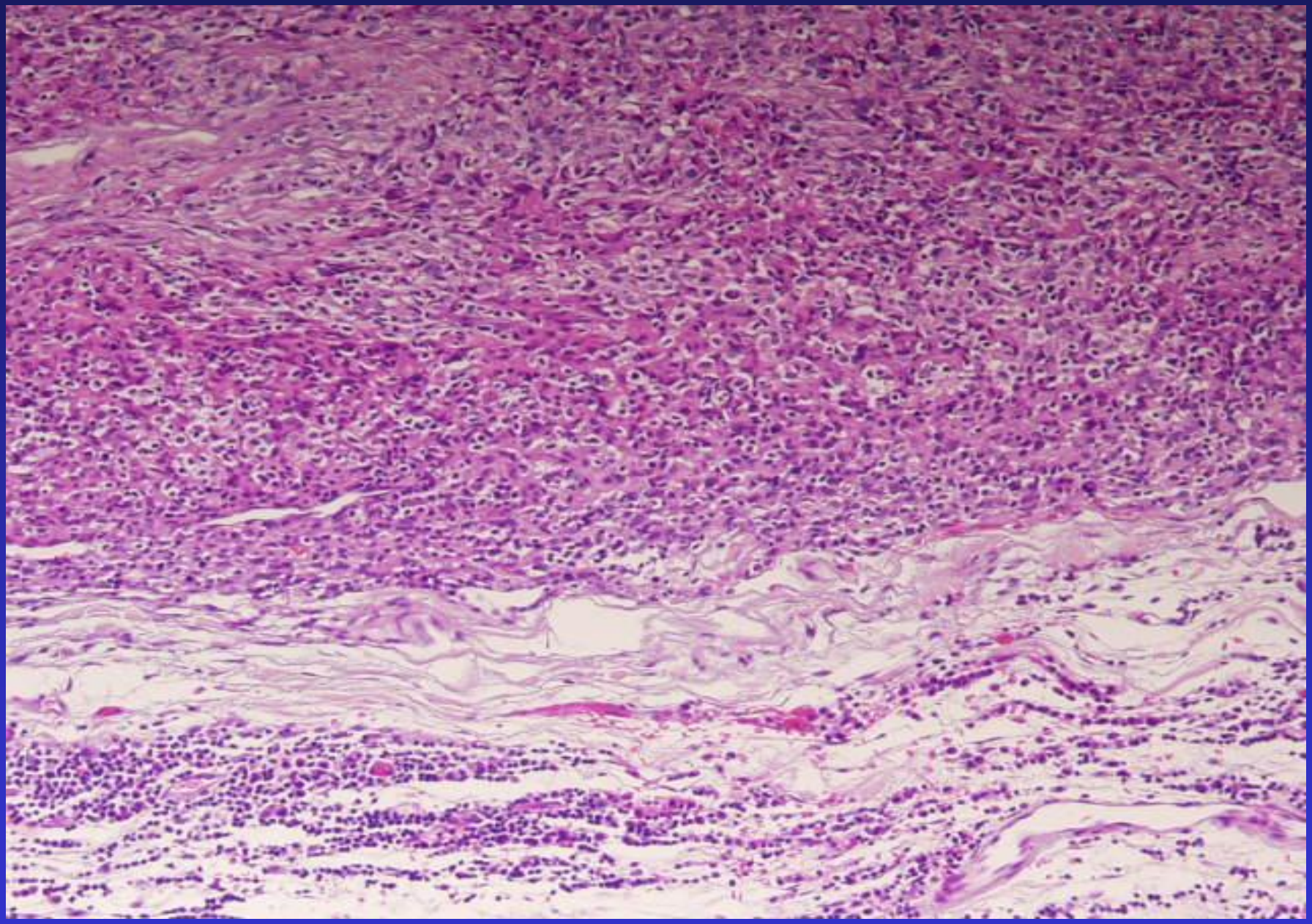

HE-4X

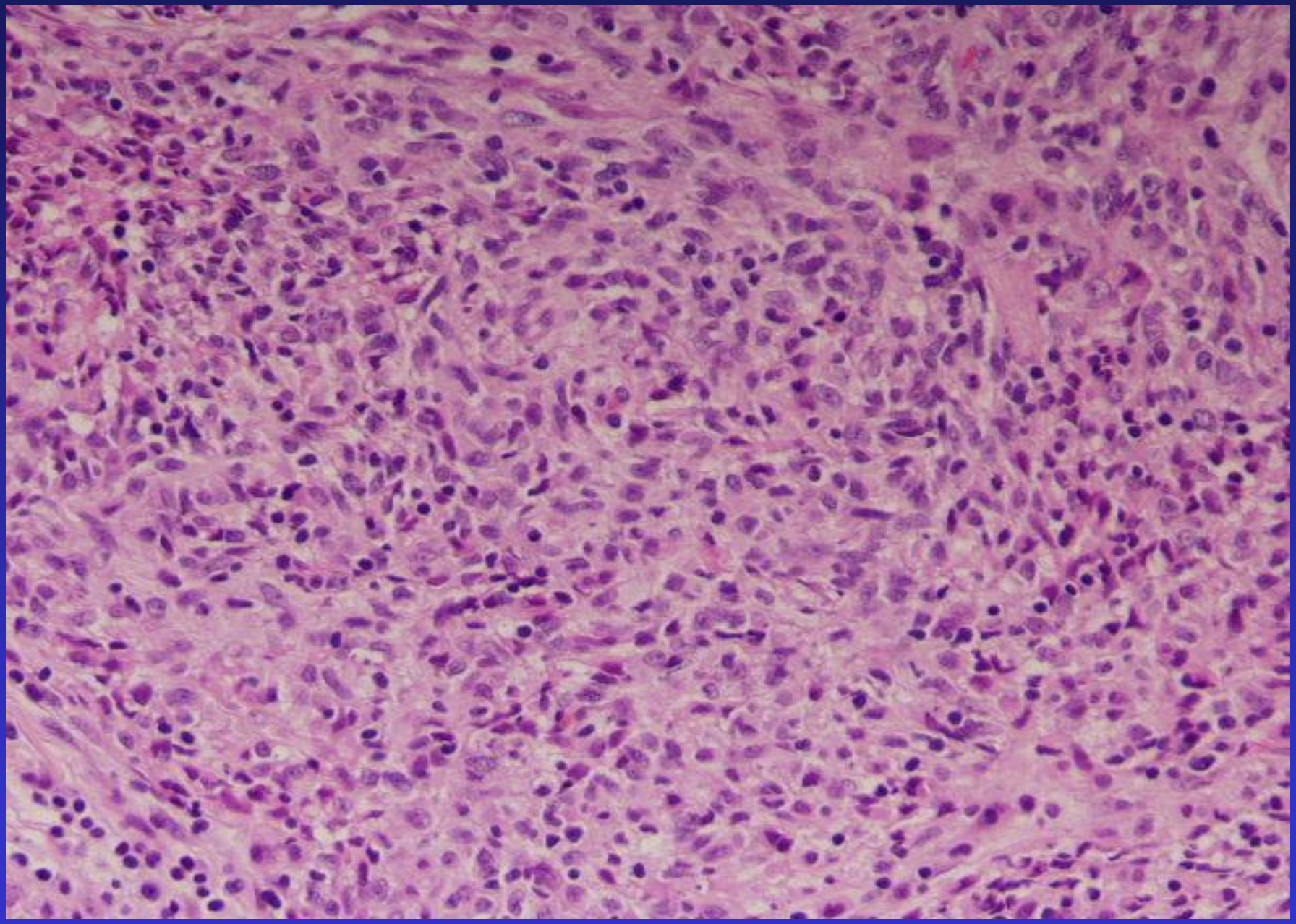

HE-20X

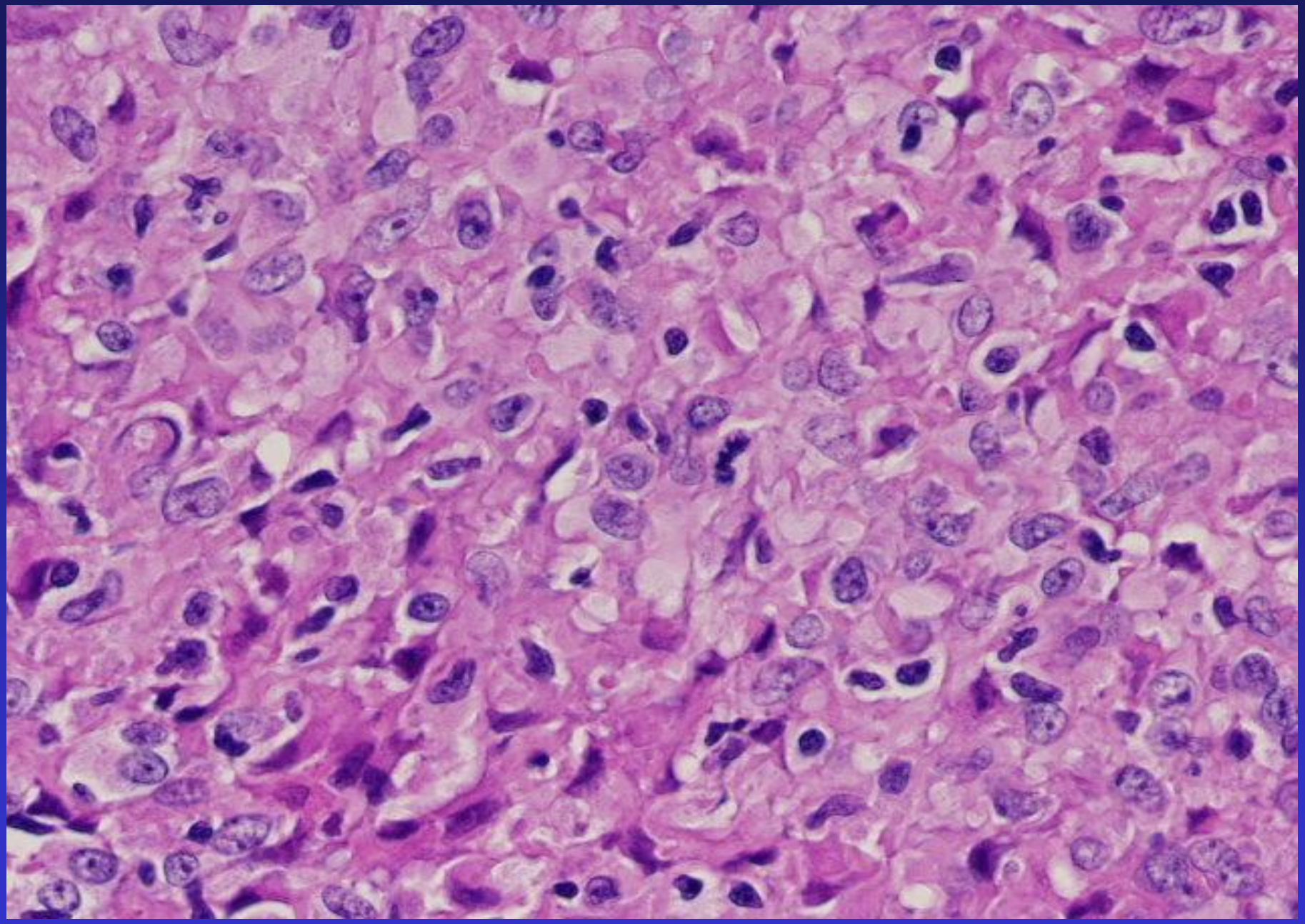

HE-40X

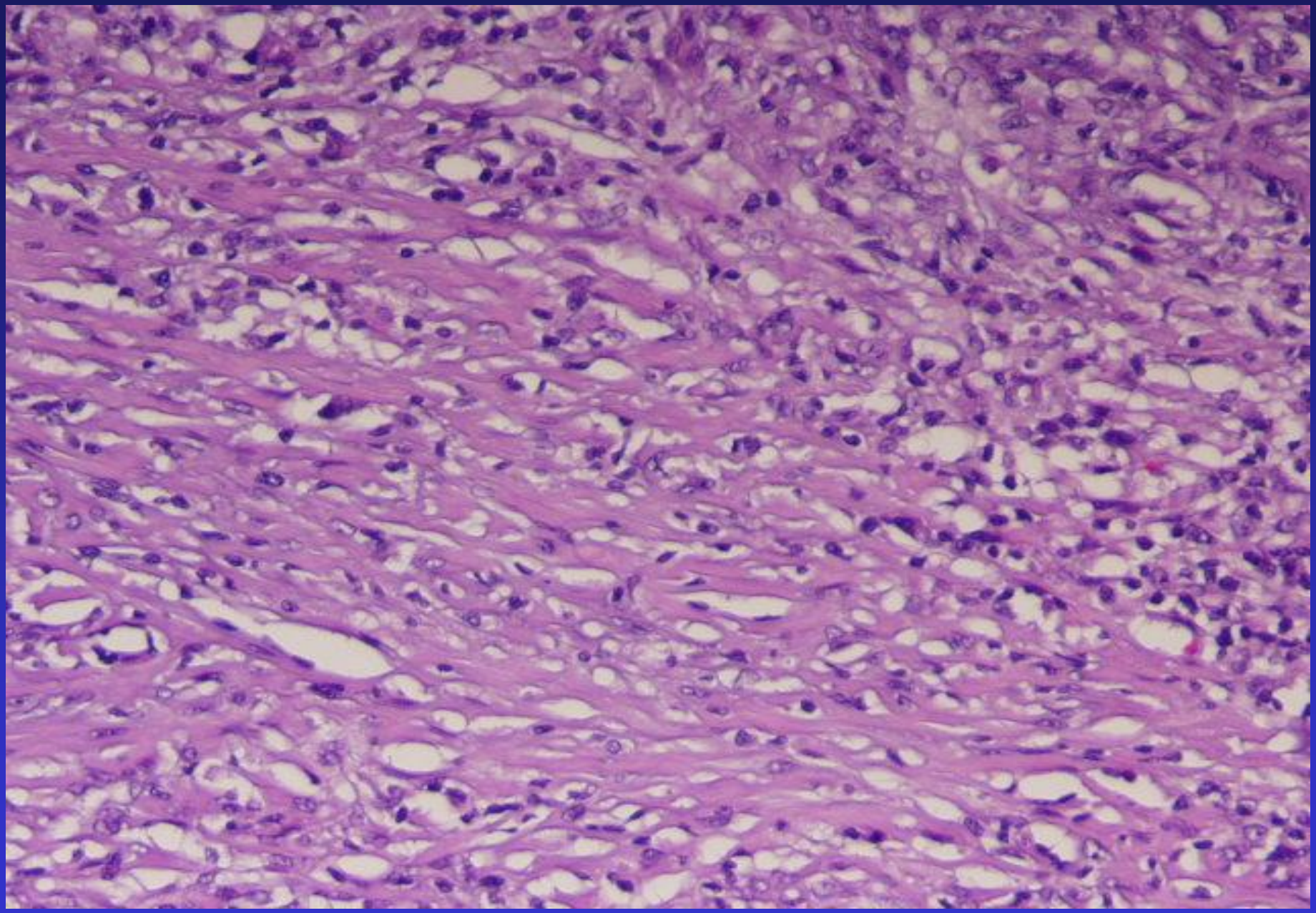

HE-20X

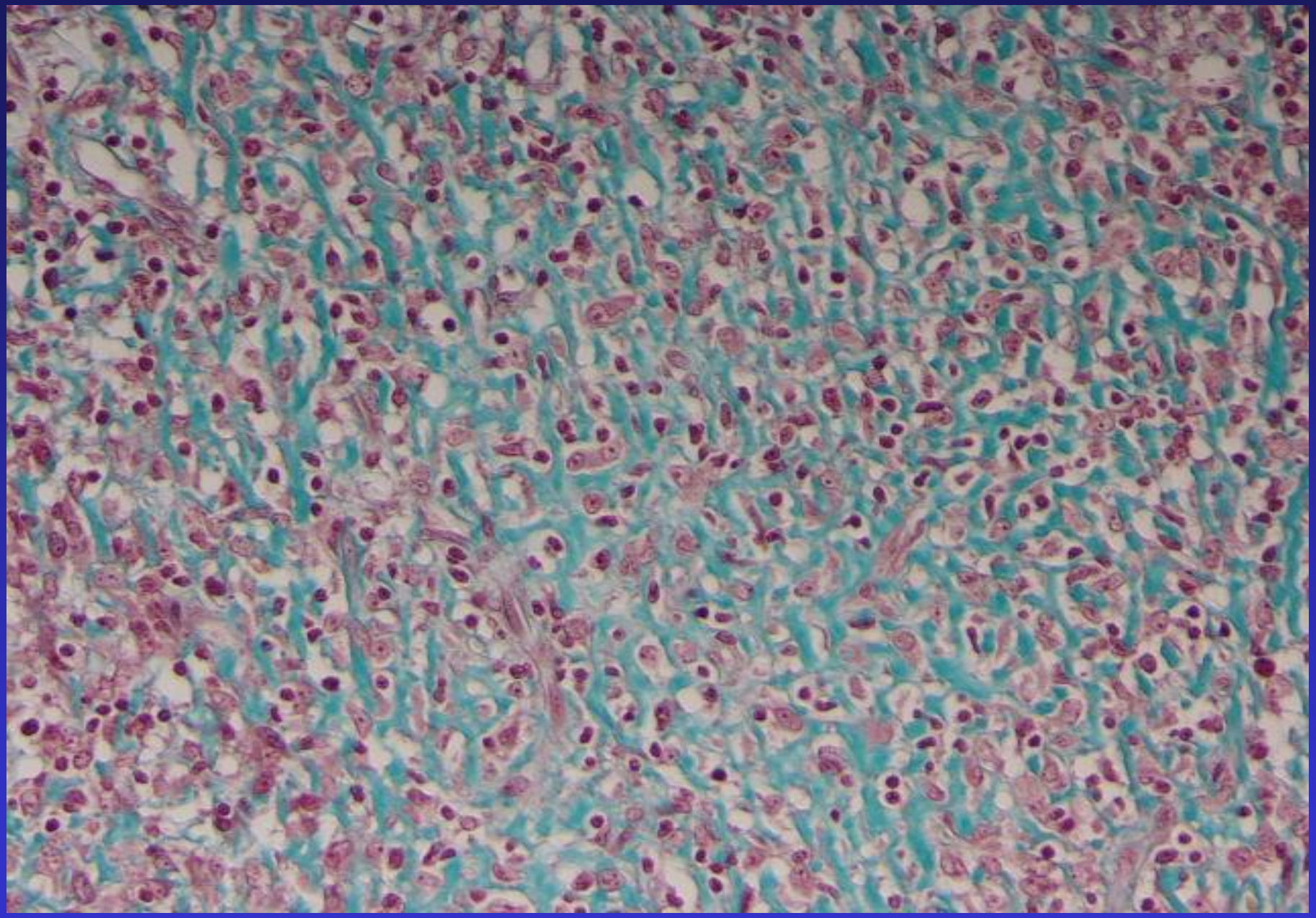

T. DE MASSON-20X

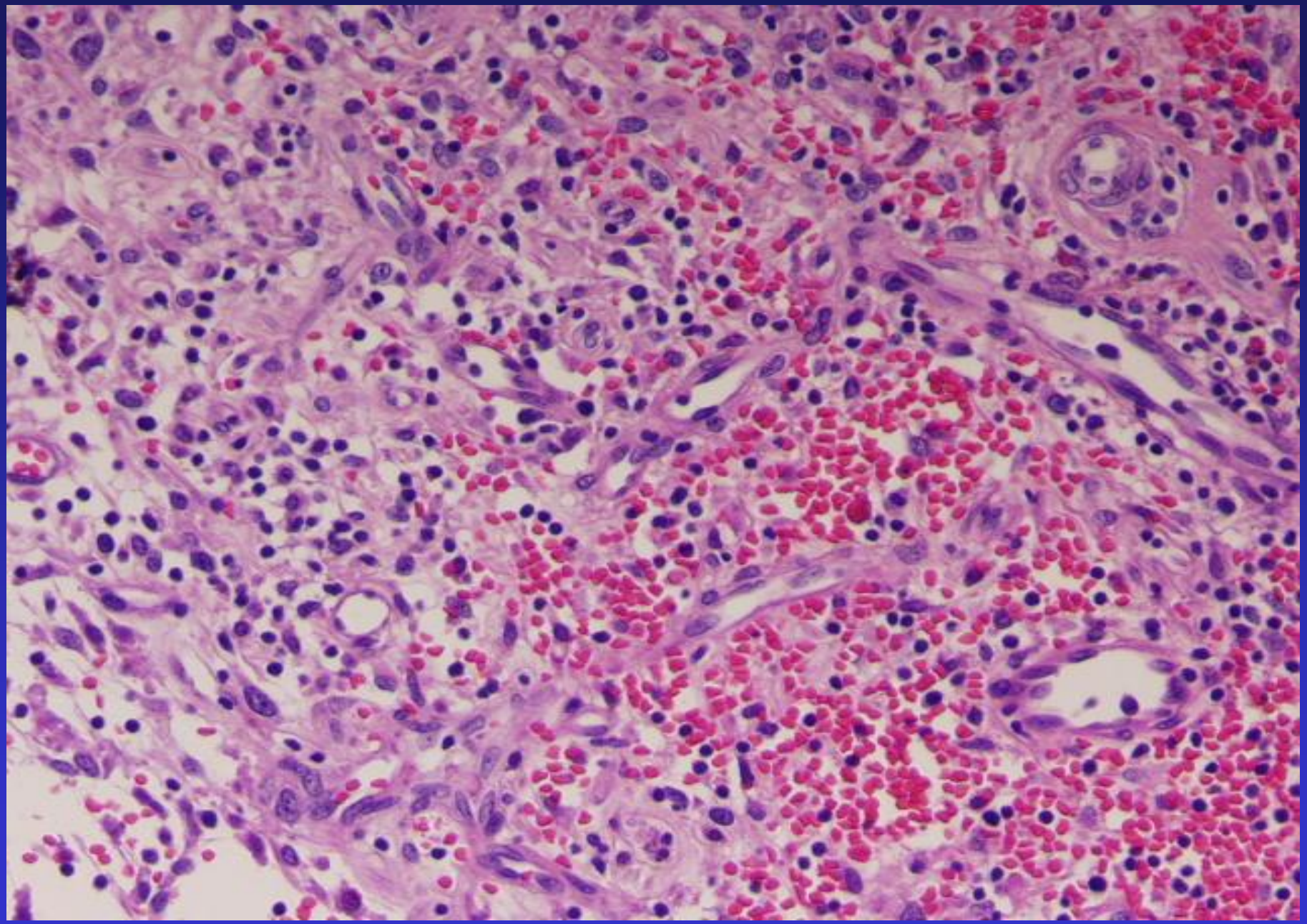

HE-20X

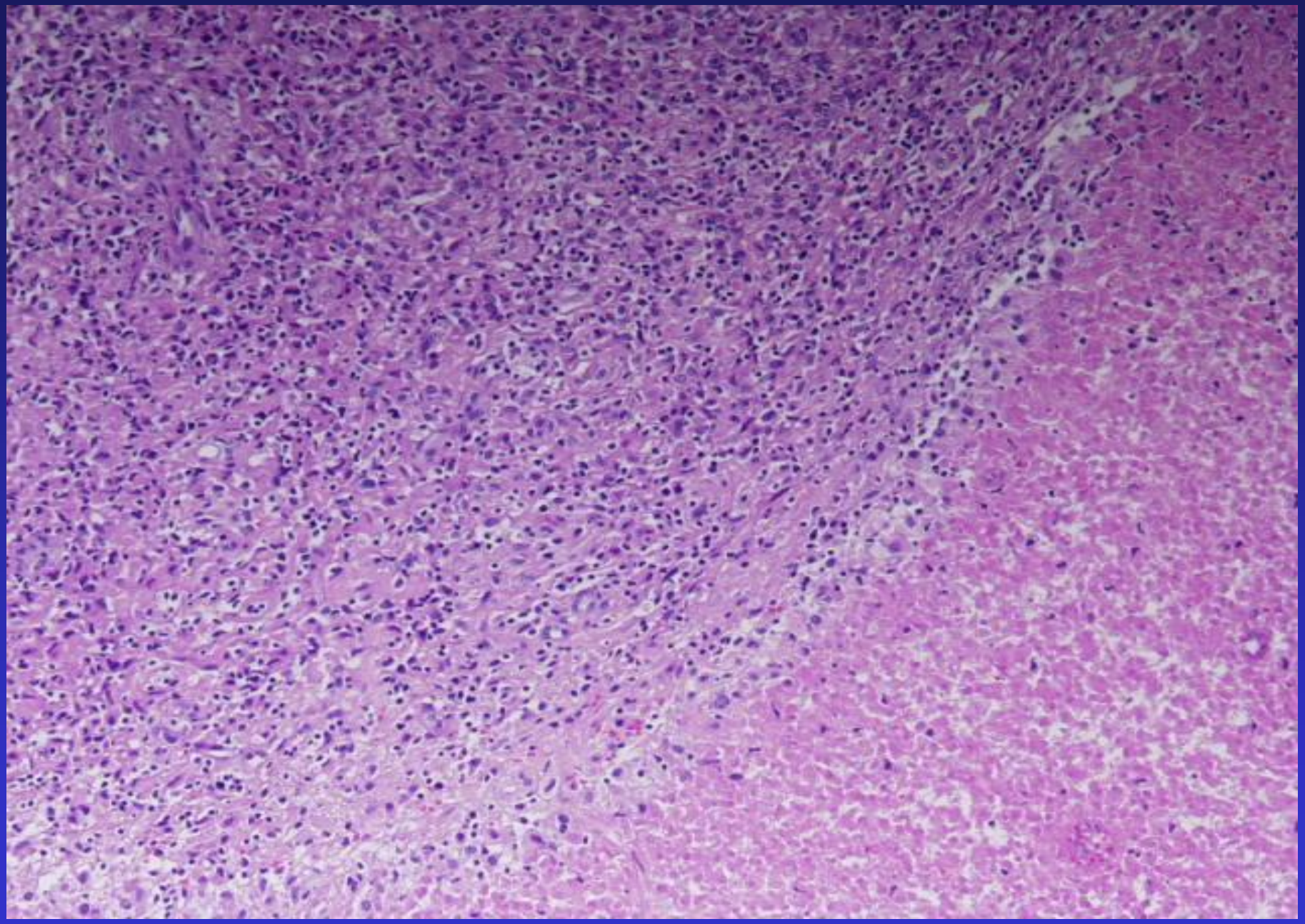

HE-4X

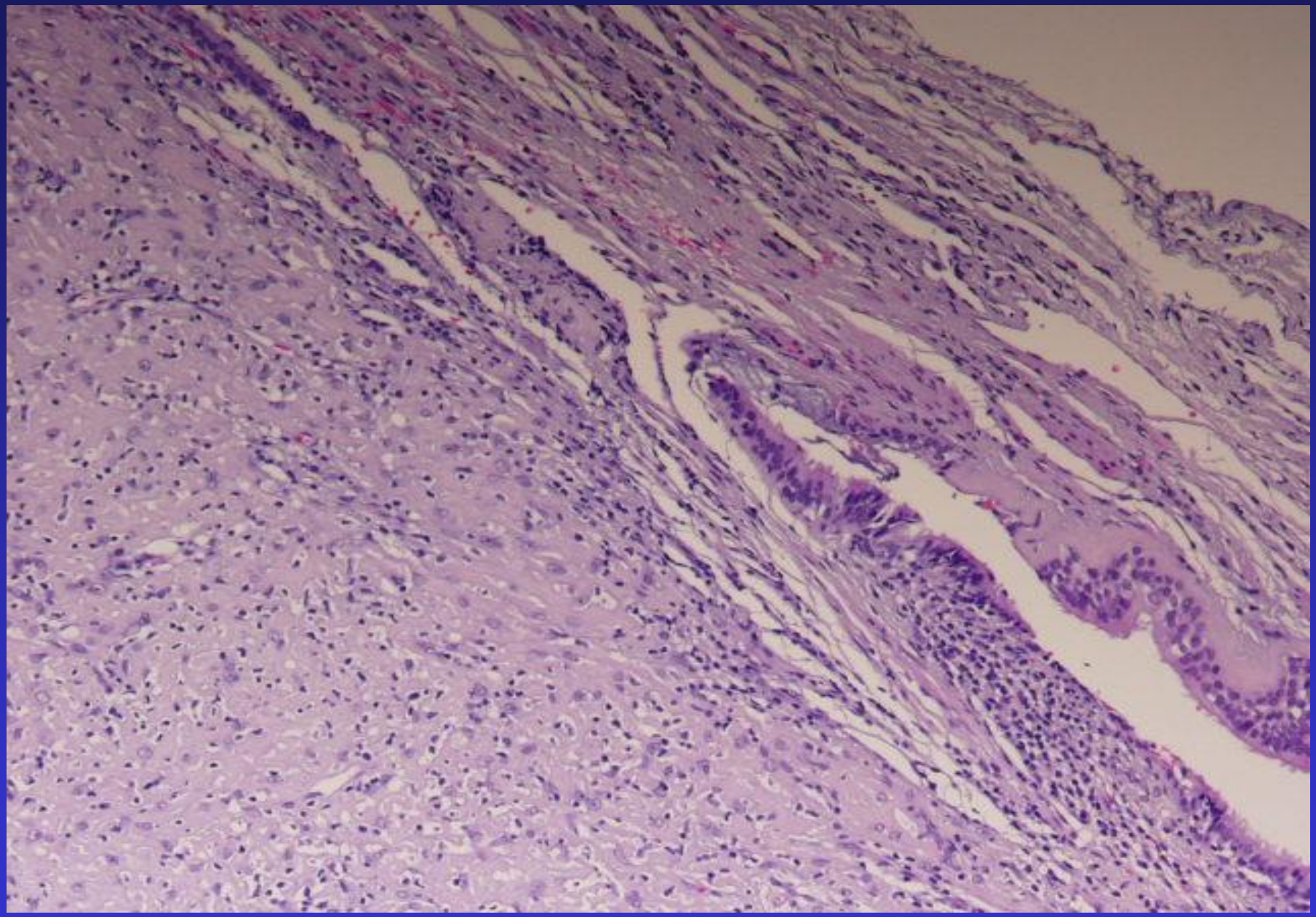

Toracotomia derecha (01B241)

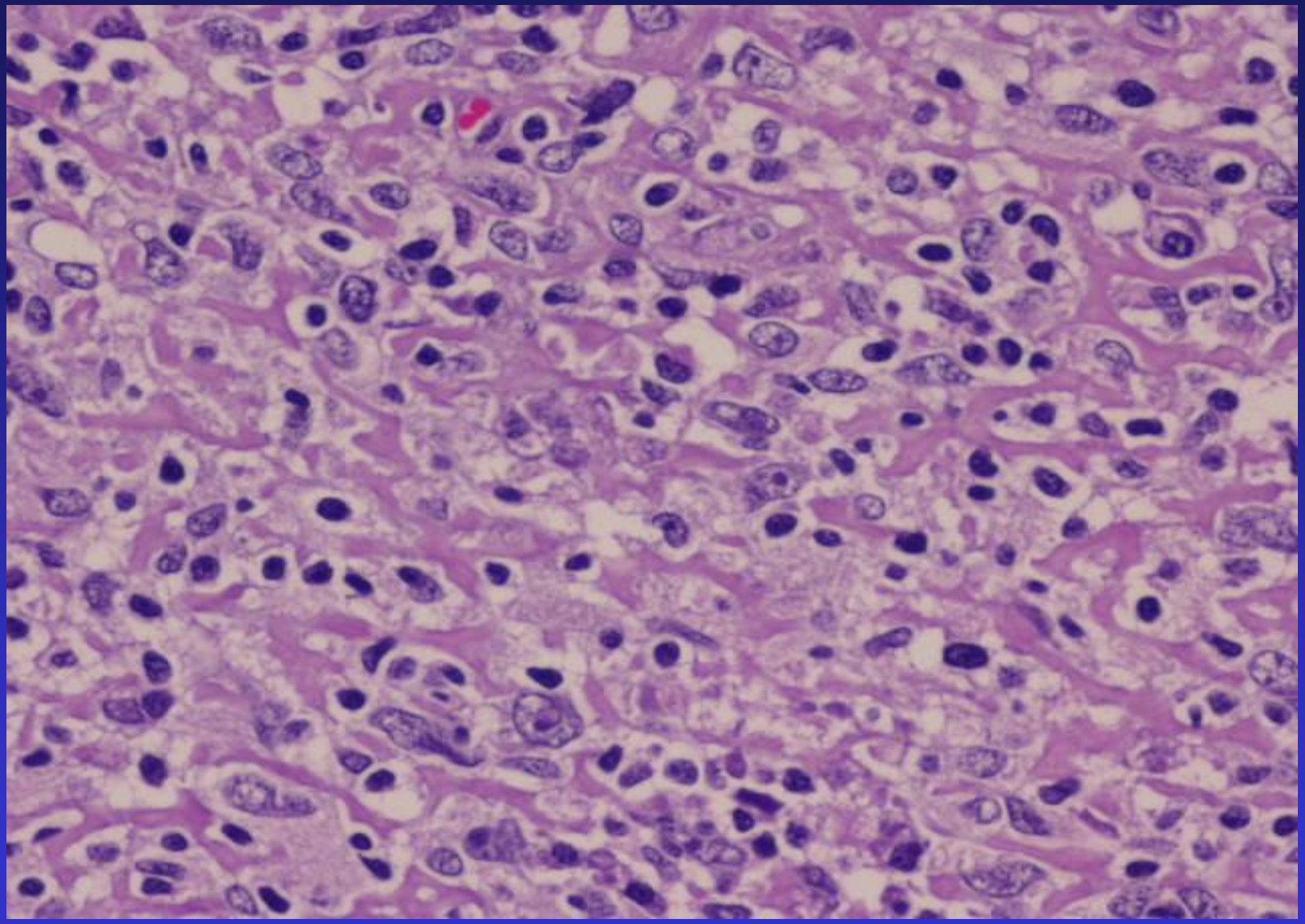

HE-40X

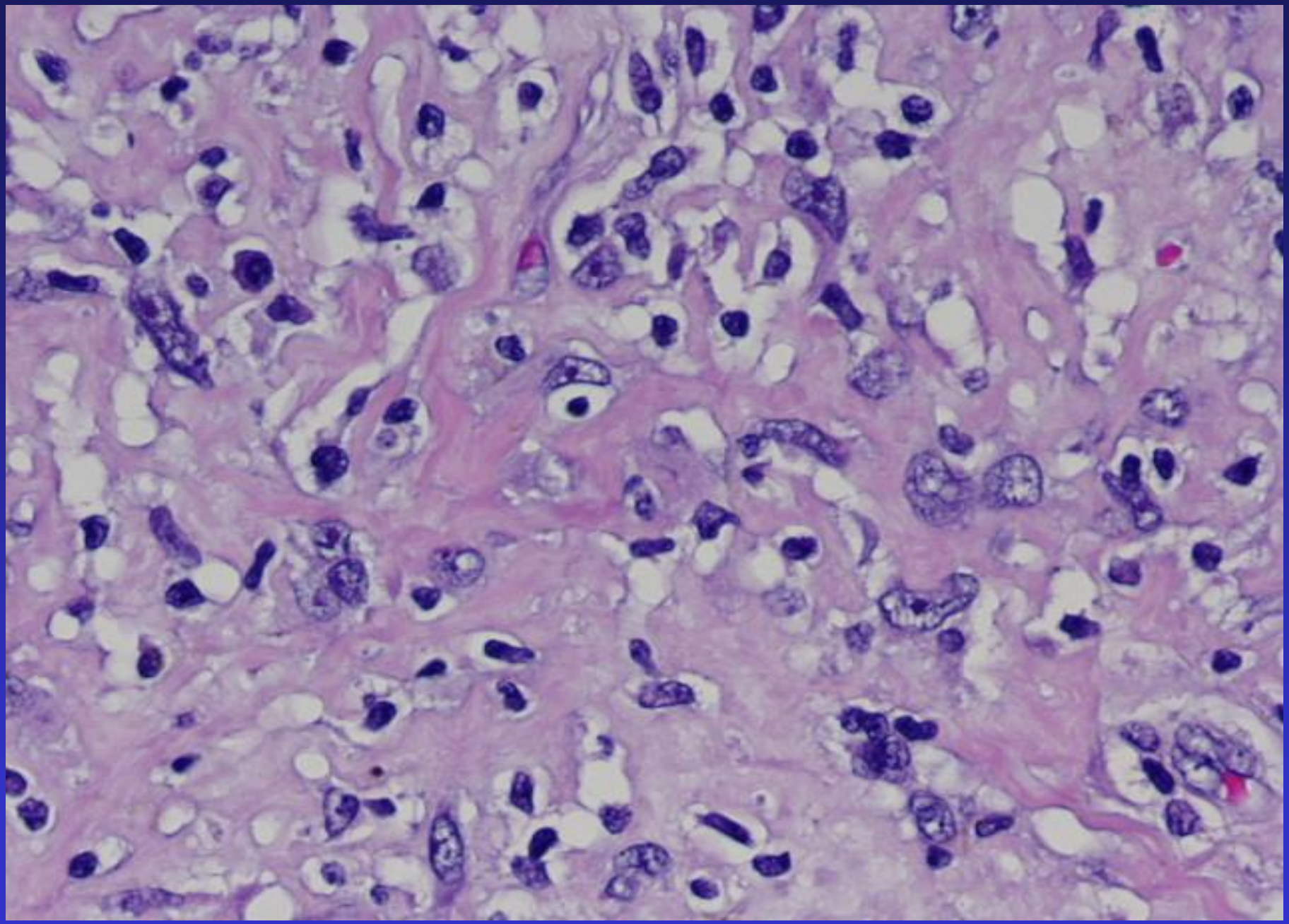

HE-40X

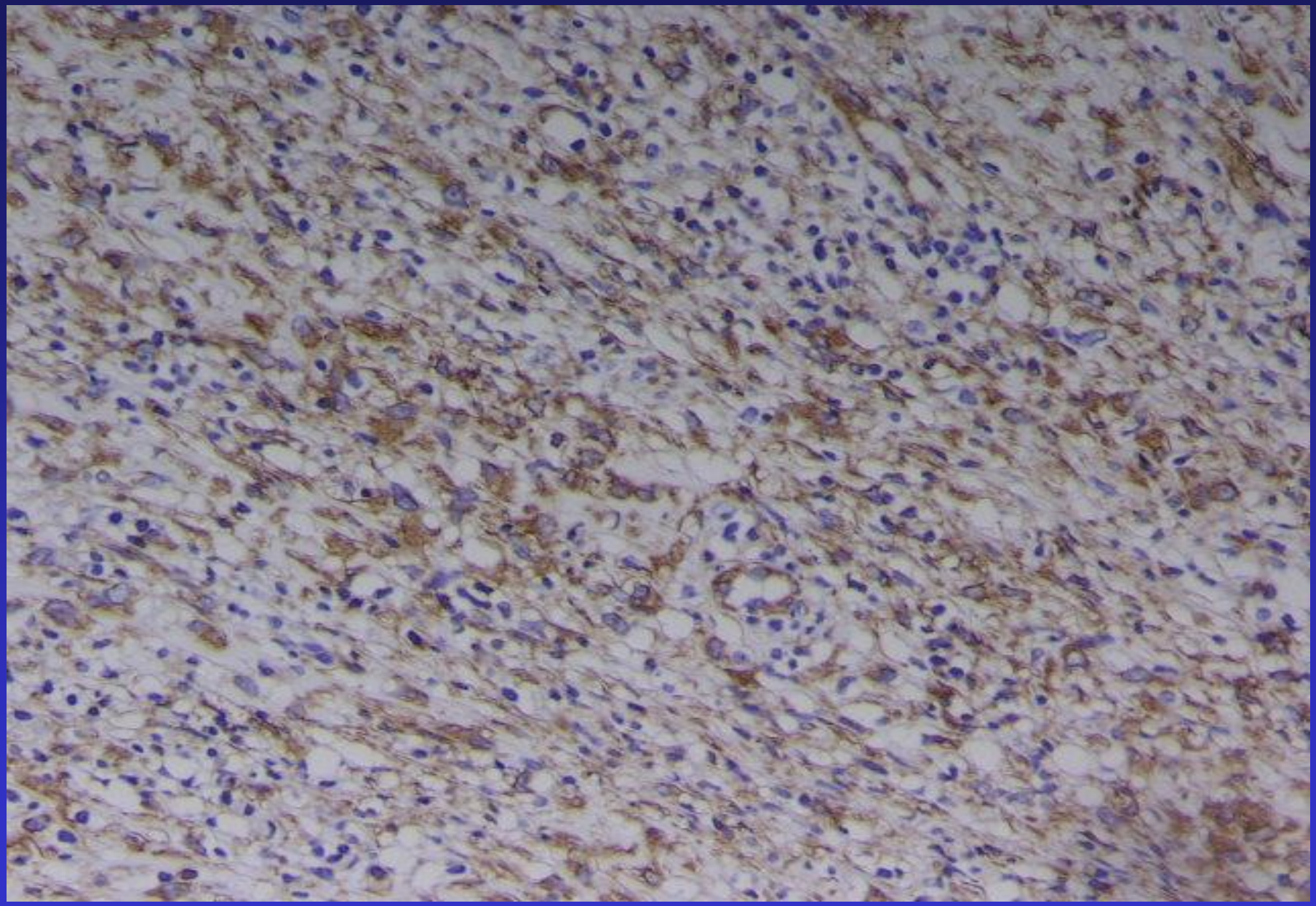

VIMENTINA-10X

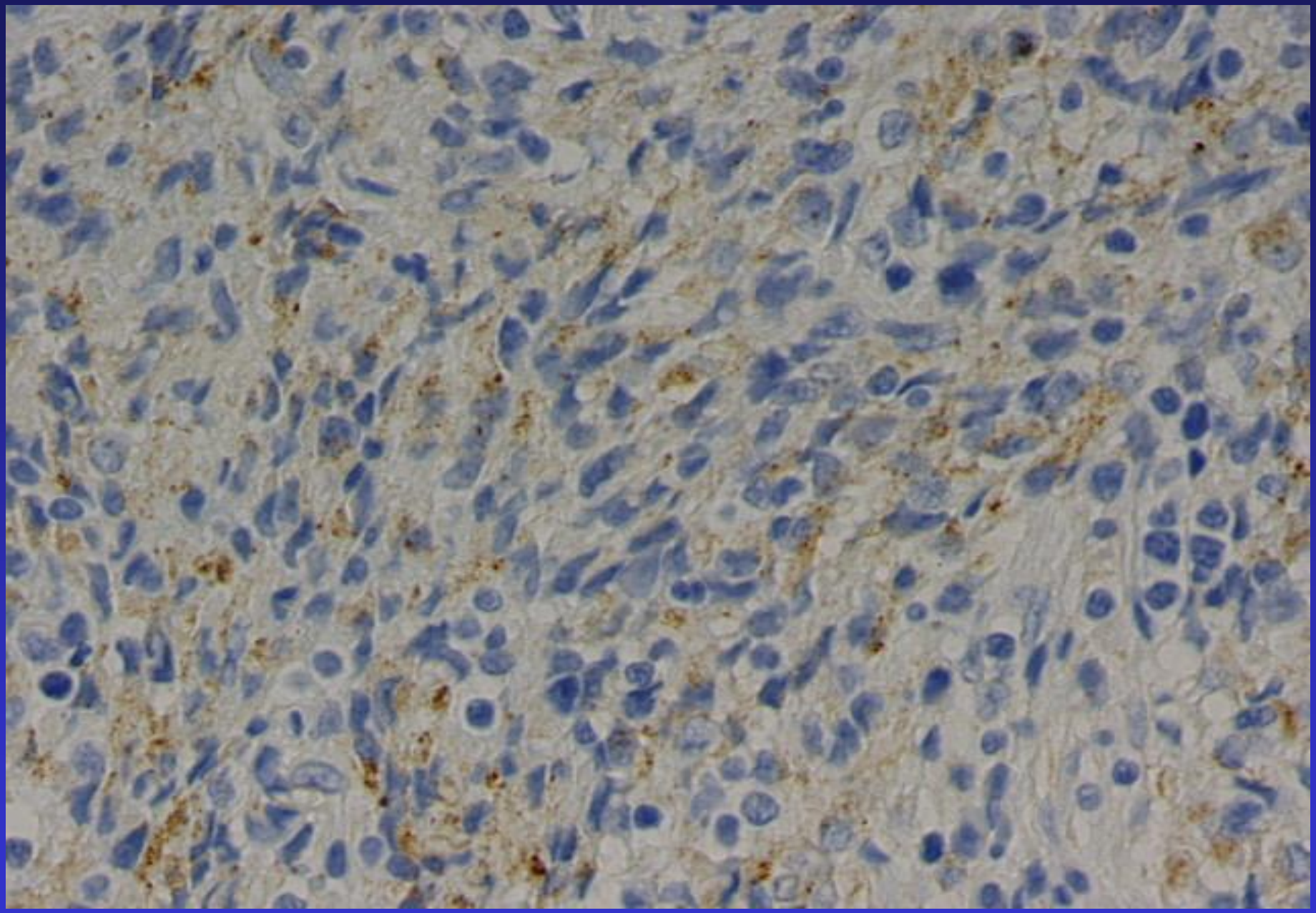

EMA-40X

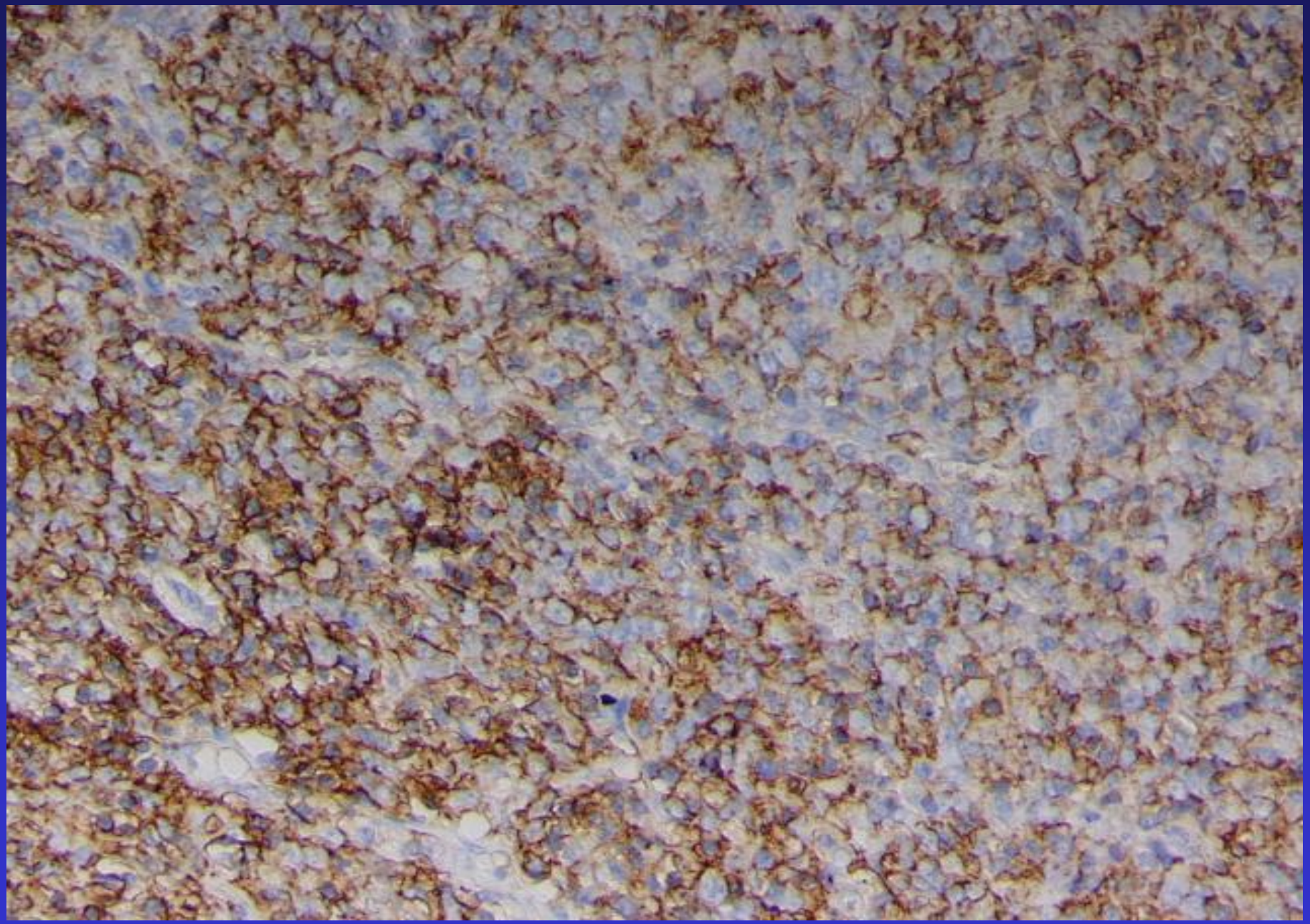

CD99-20X

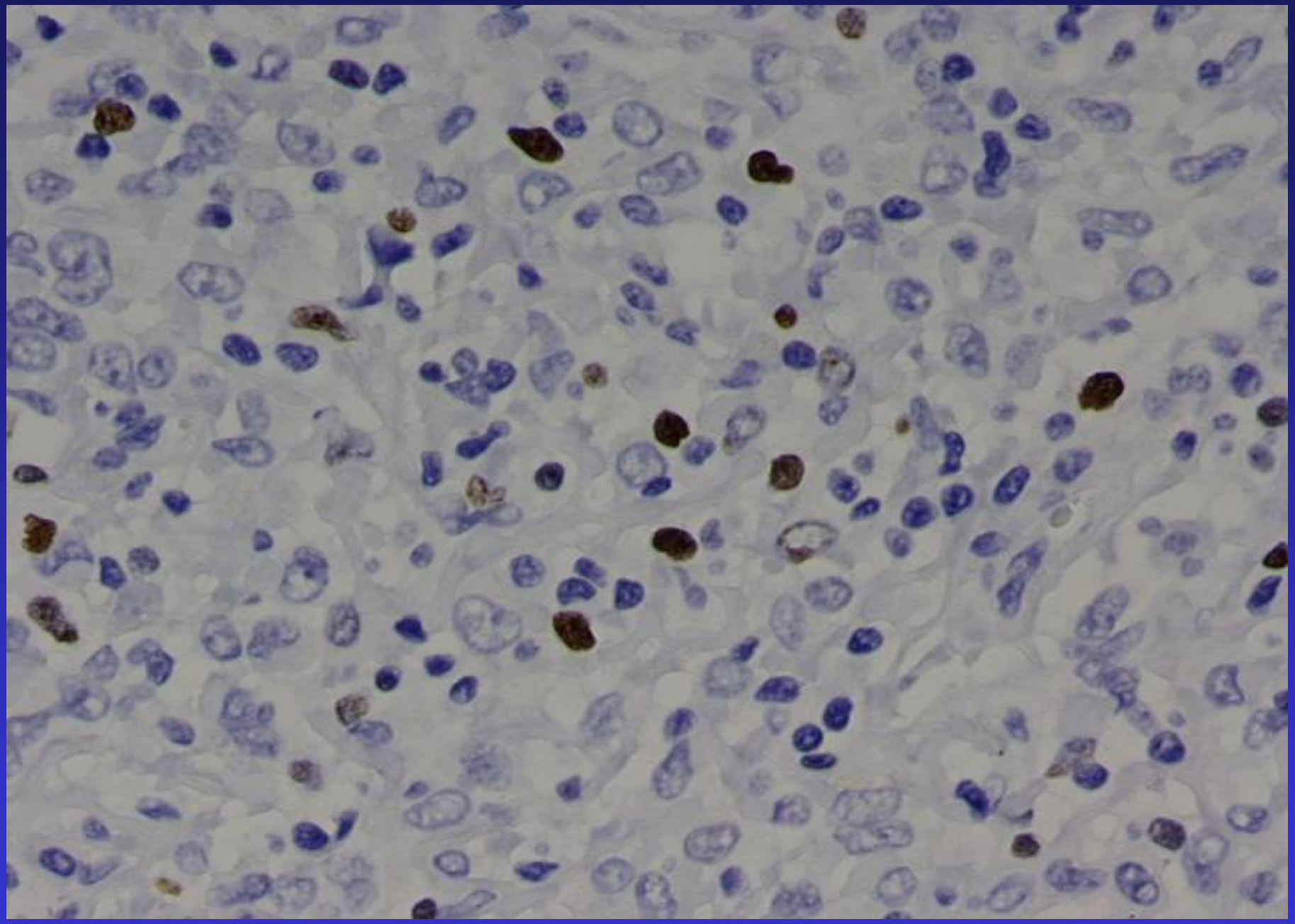

MIB1-40X

INMUNOHISTOQUÍMICA

- Vimentina +
- EMA focalmente +
- CD99 patrón de Mb +
- KI-67 20%

- Queratinas -
- Actina, Desmina -
- S-100 -
- CD68 -
- CD21 -
- P53 -
- Bcl2 -

D. DIFERENCIAL

- **Sarcoma sinovial: SYT-SSX negativo**
- **Fibrosarcoma epitelioide esclerosante.**

FIBROSARCOMA EPITELIOIDE ESCLEROSANTE

- T de partes blandas(Kindblom y cols,1995)
- Afecta a musculatura profunda
- Asociado a fascia adyacente y periostio
- Localización: EEII y tronco
- Tamaño: 9cm.

FIBROSARCOMA EPITELIOIDE ESCLEROSANTE
MICROSCOPÍA

- Zonas convencionales de fibrosarcoma
- Células ovoides, citoplasmas claros
- Estroma fibroso hialinizado
- M. Electrónica: fibroblastos
- Inmunohistoquímica: vimentina
- E. Molecular: 12q13, 12q15 (sarcomas)

FIBROSARCOMA EPITELIOIDE ESCLEROSANTE
D. DIFERENCIAL

- **Metástasis de carcinoma**
- **Sarcoma sinovial: SYT-SSX positivo**
- **Proliferaciones fibroblásticas benignas**
- **Fibrosarcomas de bajo grado.**

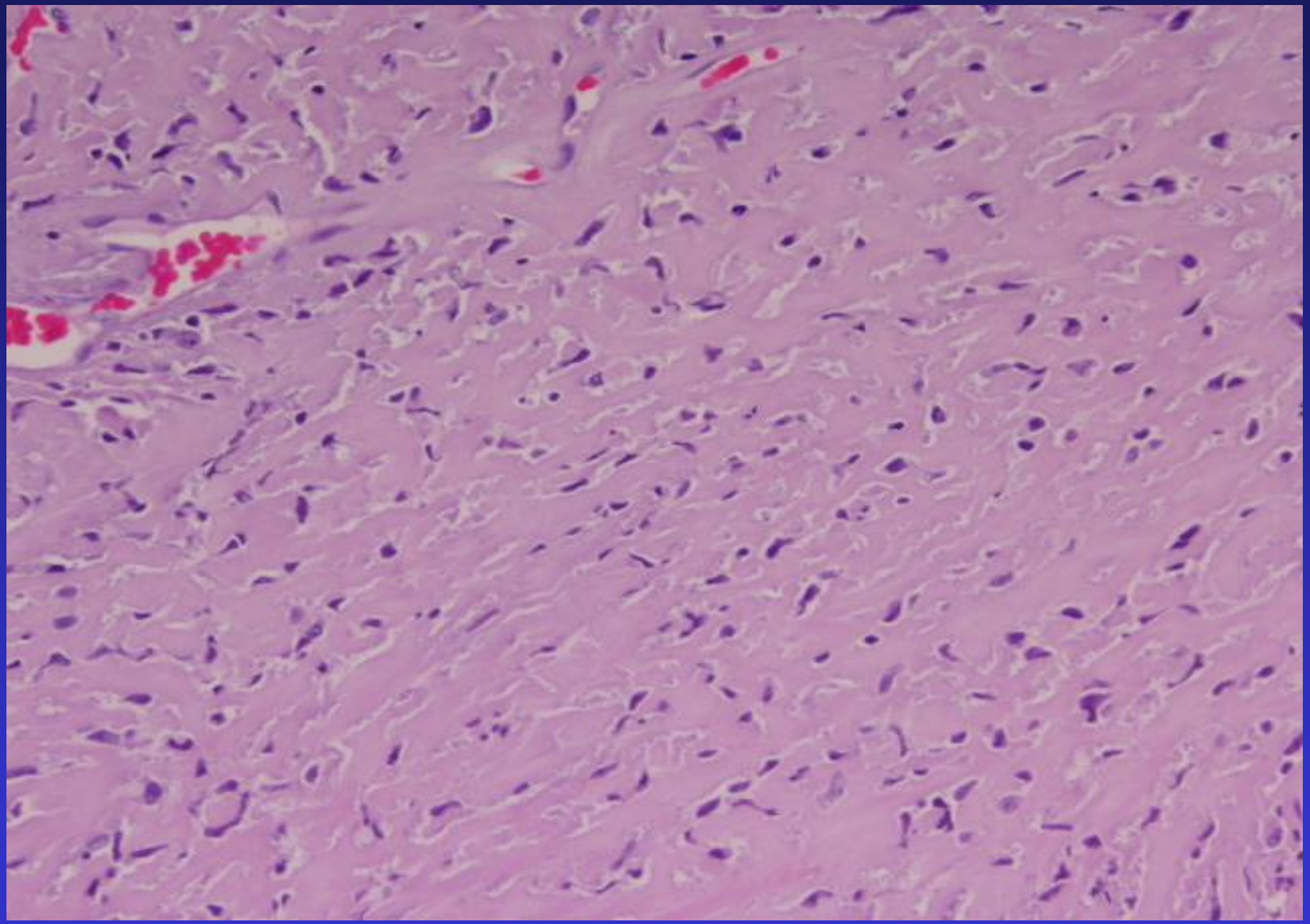

T. PARED TORÁCICA (02B-572)

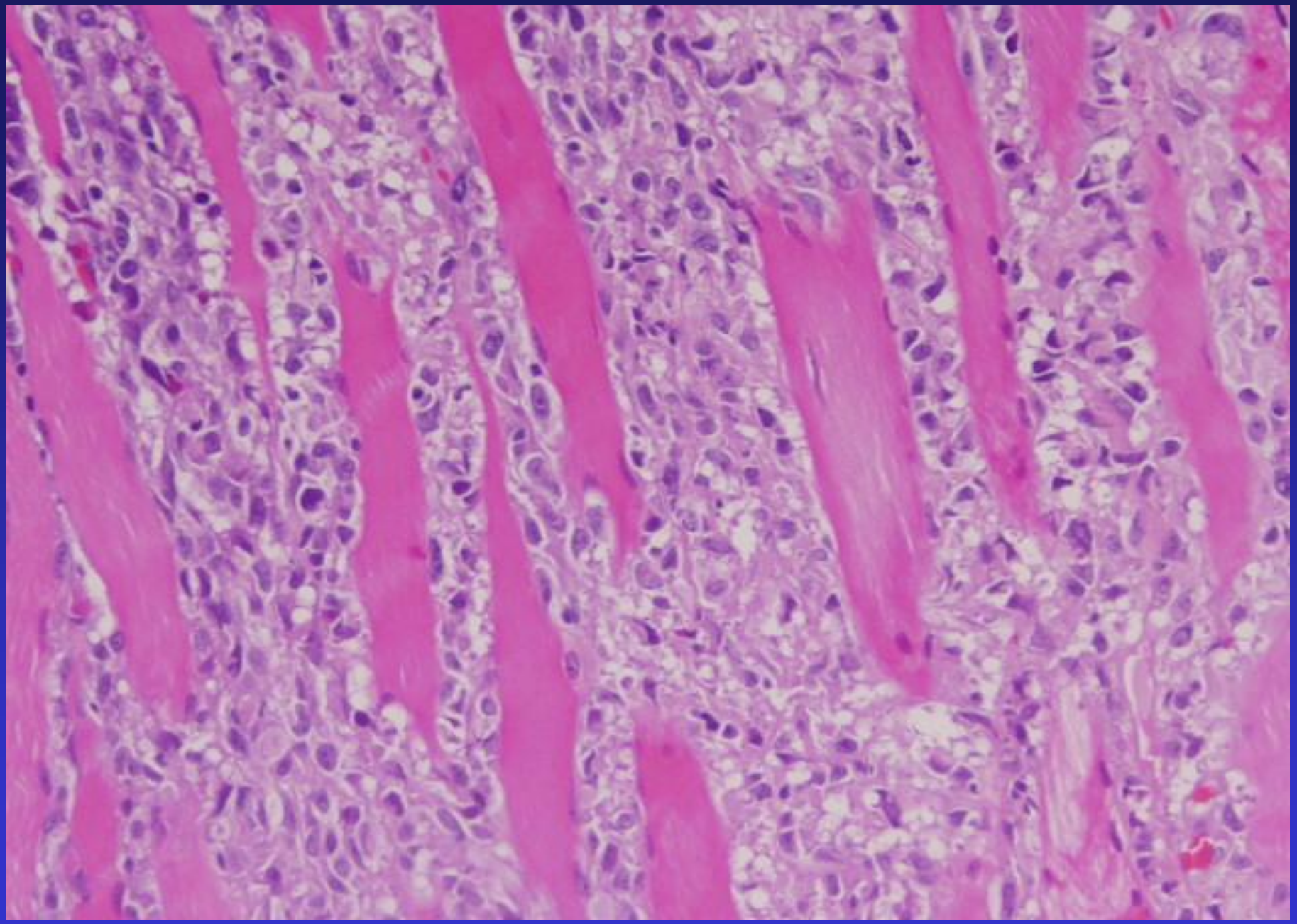

T. PARED TORÁCICA (02B572)

FIBROSARCOMA EPITELIOIDE ESCLEROSANTE
PRONÓSTICO
(Antonescu y cols, 2001)

- 50% recurrencia local y enf. Persistente
- 86% metástasis en pulmon, hueso etc.
- 57% mortalidad (1-7 años).
- Excisión quirúrgica amplía
- Radioterapia y quimioterapia adyuvante.