Caso 4

Cristina Alenda González
Hospital General Universitario de Alicante

Historia clínica

- Niño de 20 meses previamente sano con distensión abdominal y pérdida ponderal.
- Alfafetoproteína: > 100.000 UI/ml
- Plaquetas: 787.000/ml
- ECO abdominal: masa hiperecogénica el LD hepático (9.4x8.5 cm)

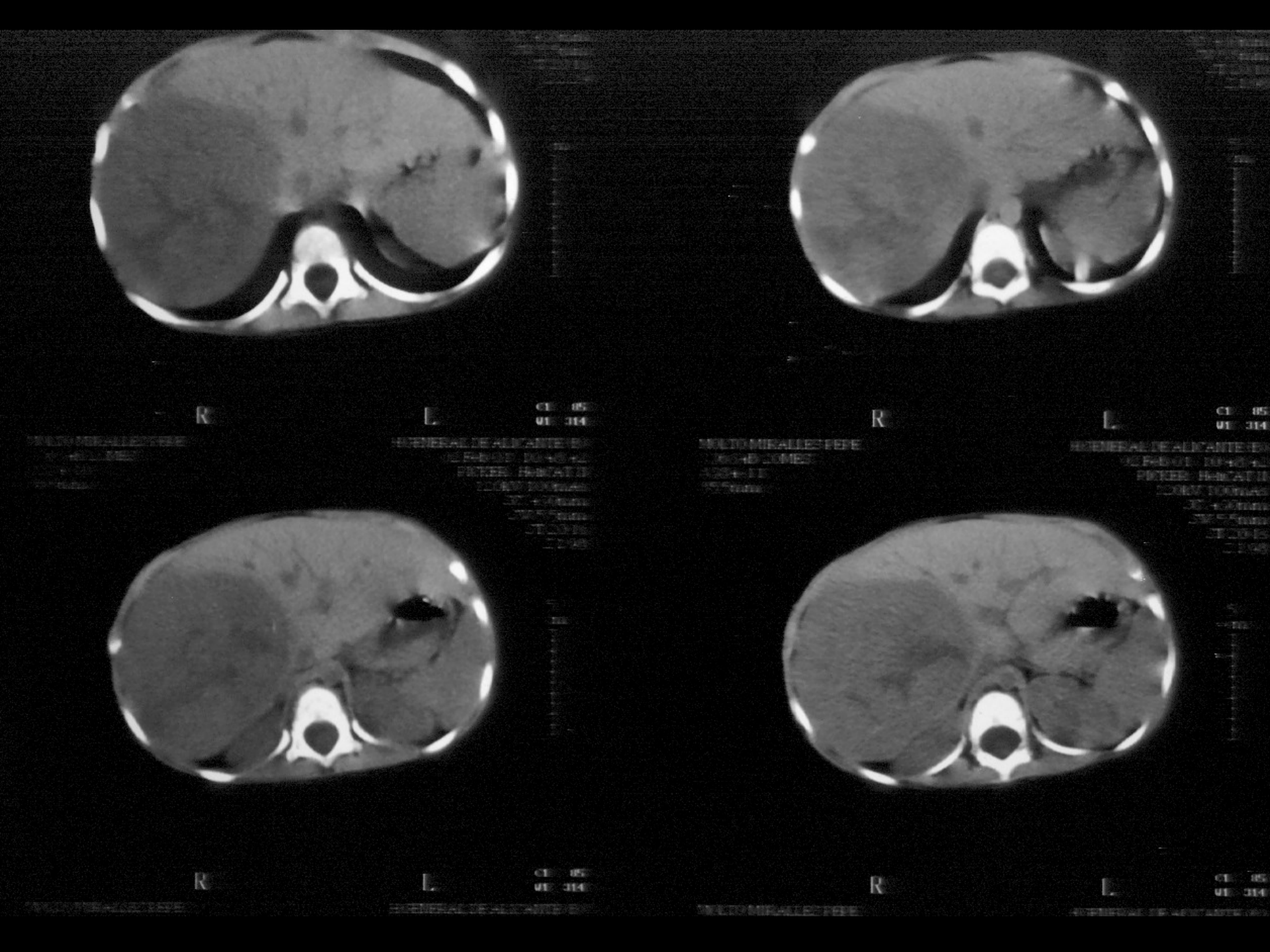
R
L
R
L
R
L
R
L

Diagnóstico clínico

Hepatoblastoma

Evolución y tratamiento

- Tratamiento quimioterápico.
- Radiología de control: reducción del tamaño (5x4x5 cm)
- Alfafetoproteína: 66 UI/ml
- Hemihepatectomía derecha

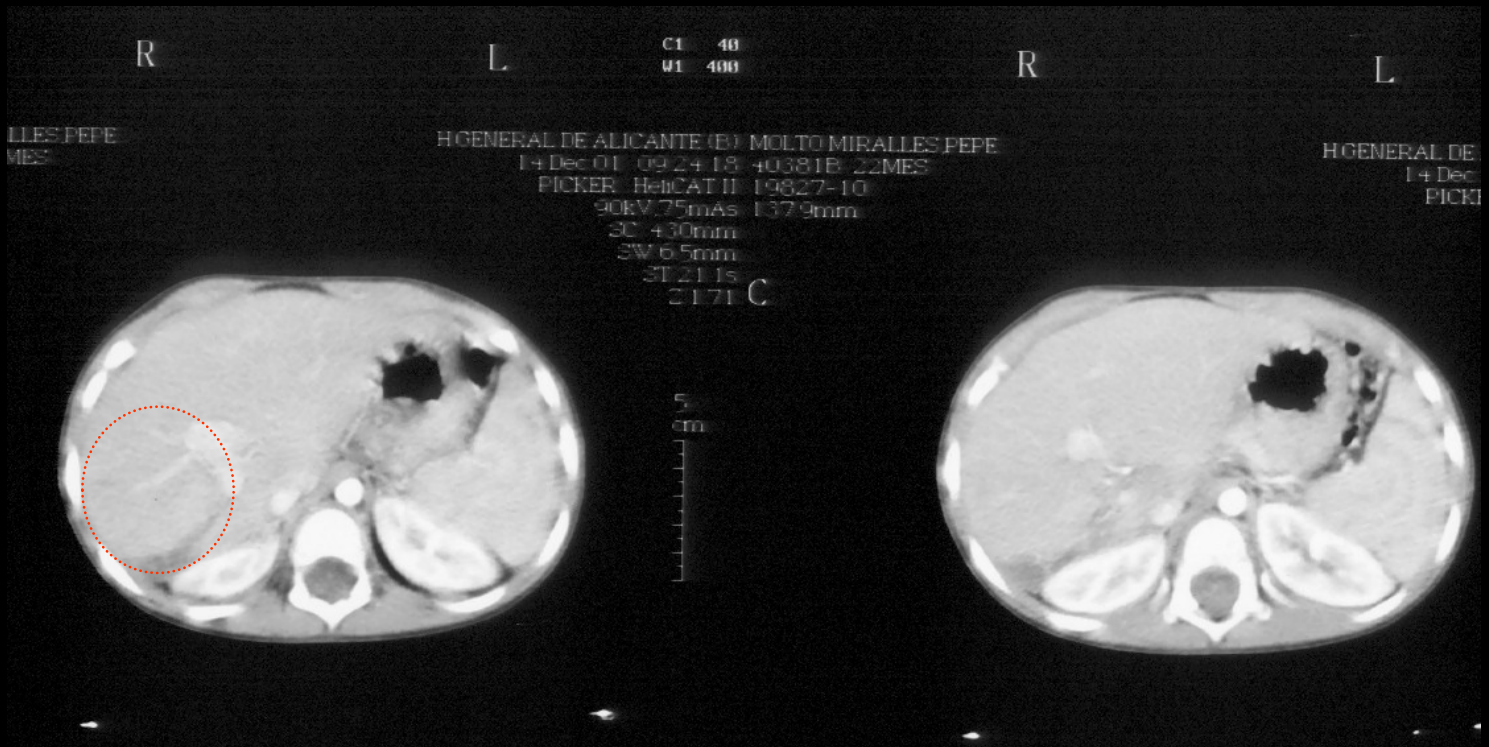
R
L
C1 40
W1 400
LLES PEPE
MES
H GENERAL DE ALICANTE (B) MOLTO MIRALLES PEPE
14 Dec 01 09:24:18 40381B 22MES
PICKER HeliCAT II 19827-10
90kV 75mAs 137.9mm
SC +30mm
SW 6.5mm
ST 2.1 1s
2 171 C
5
cm
R
L
H GENERAL DE
14 Dec
PICK

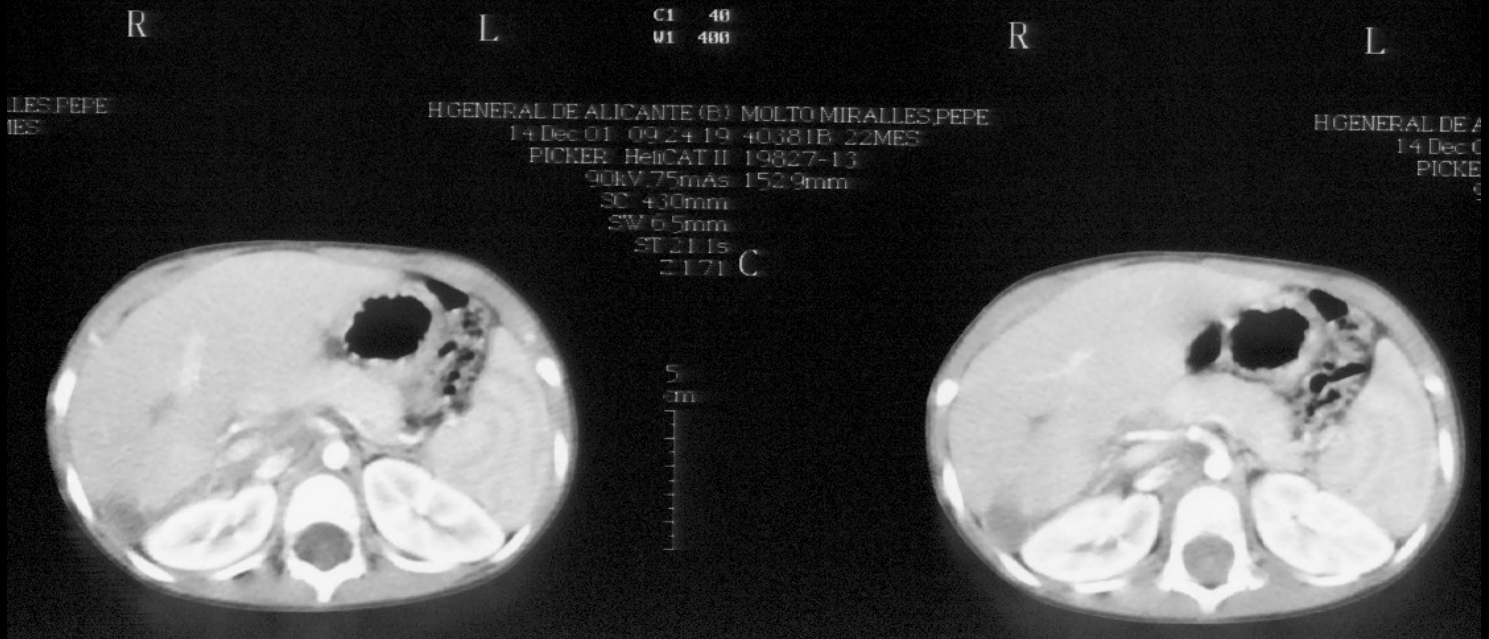
R
L
C1 40
W1 400
LLES PEPE
MES
H GENERAL DE ALICANTE (B) MOLTO MIRALLES PEPE
14 Dec 01 09:24:19 40381B 22MES
PICKER HeliCAT II 19827-13
90kV 75mAs 152.9mm
SC +30mm
SW 6.5mm
ST 2.1 1s
2 171 C
5
cm
R
L
H GENERAL DE A
14 Dec
PICKE

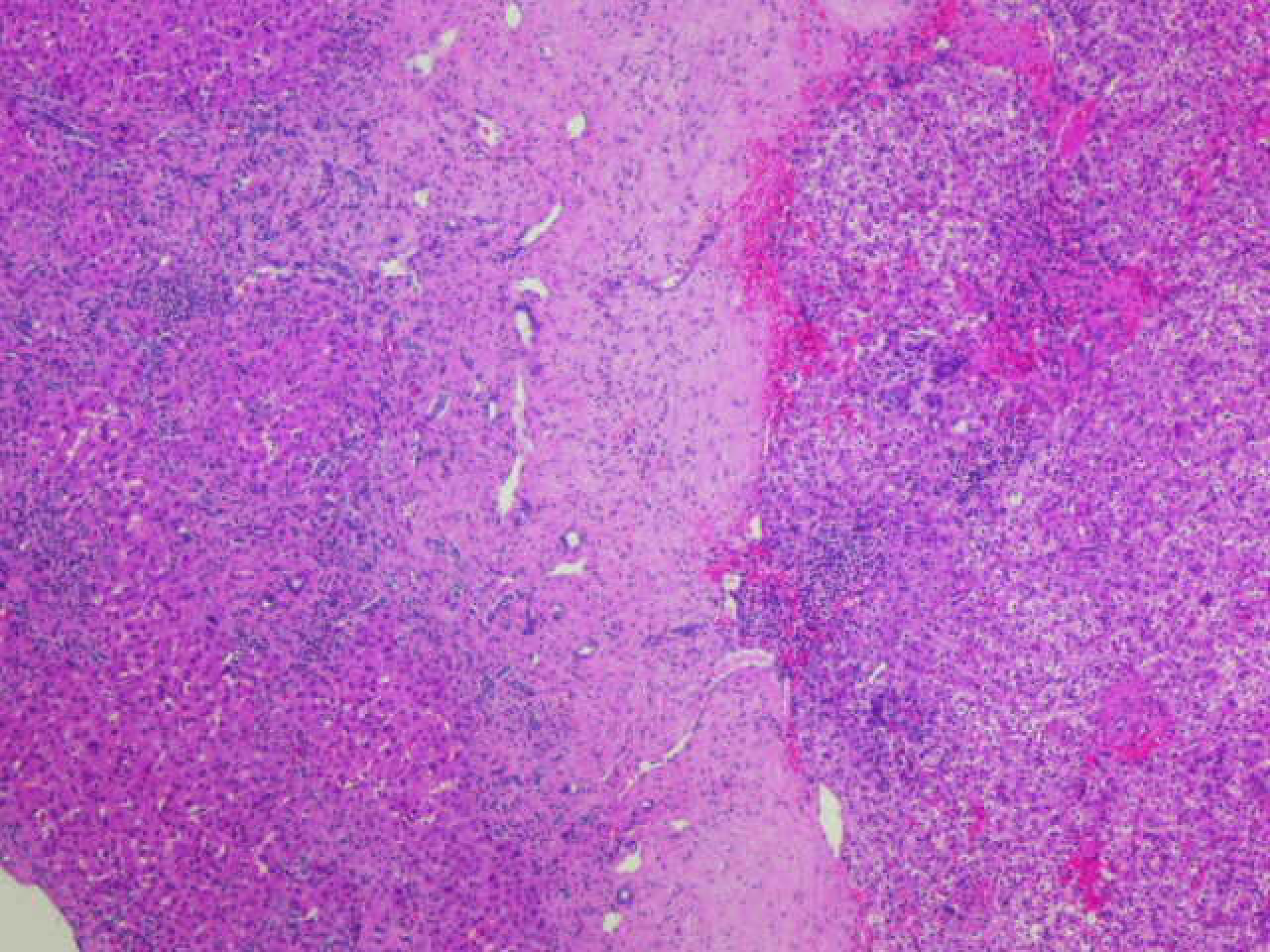

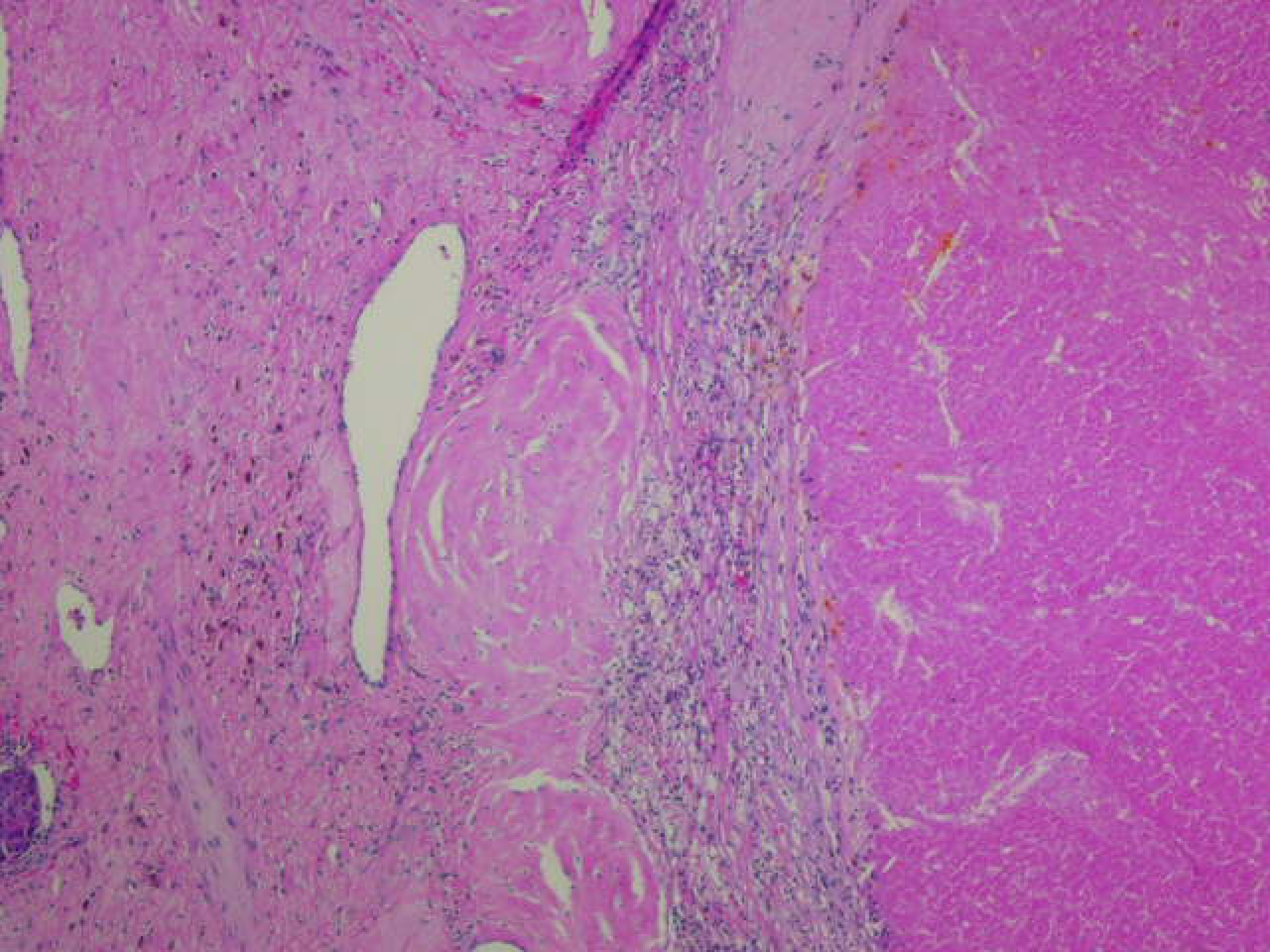

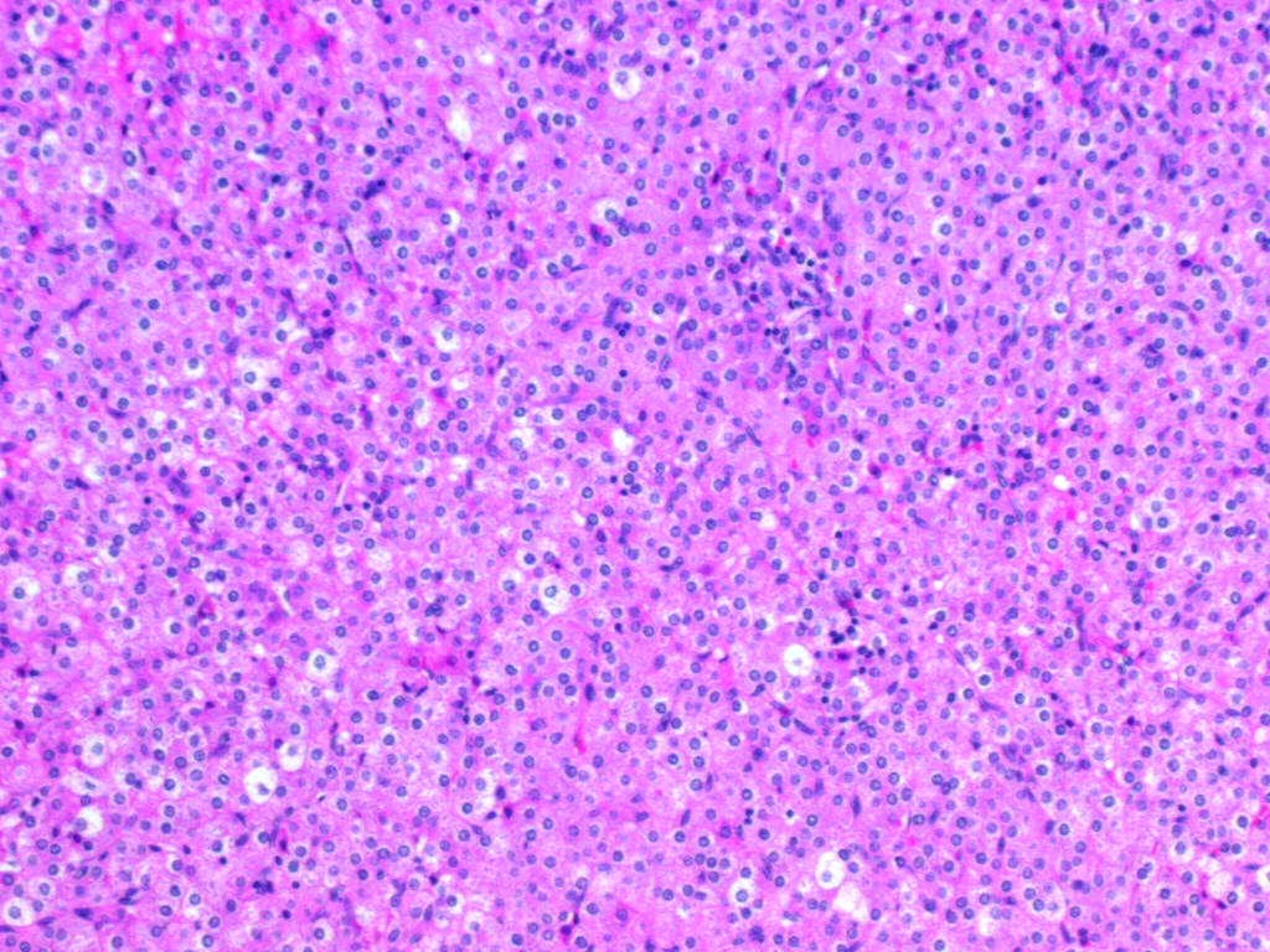

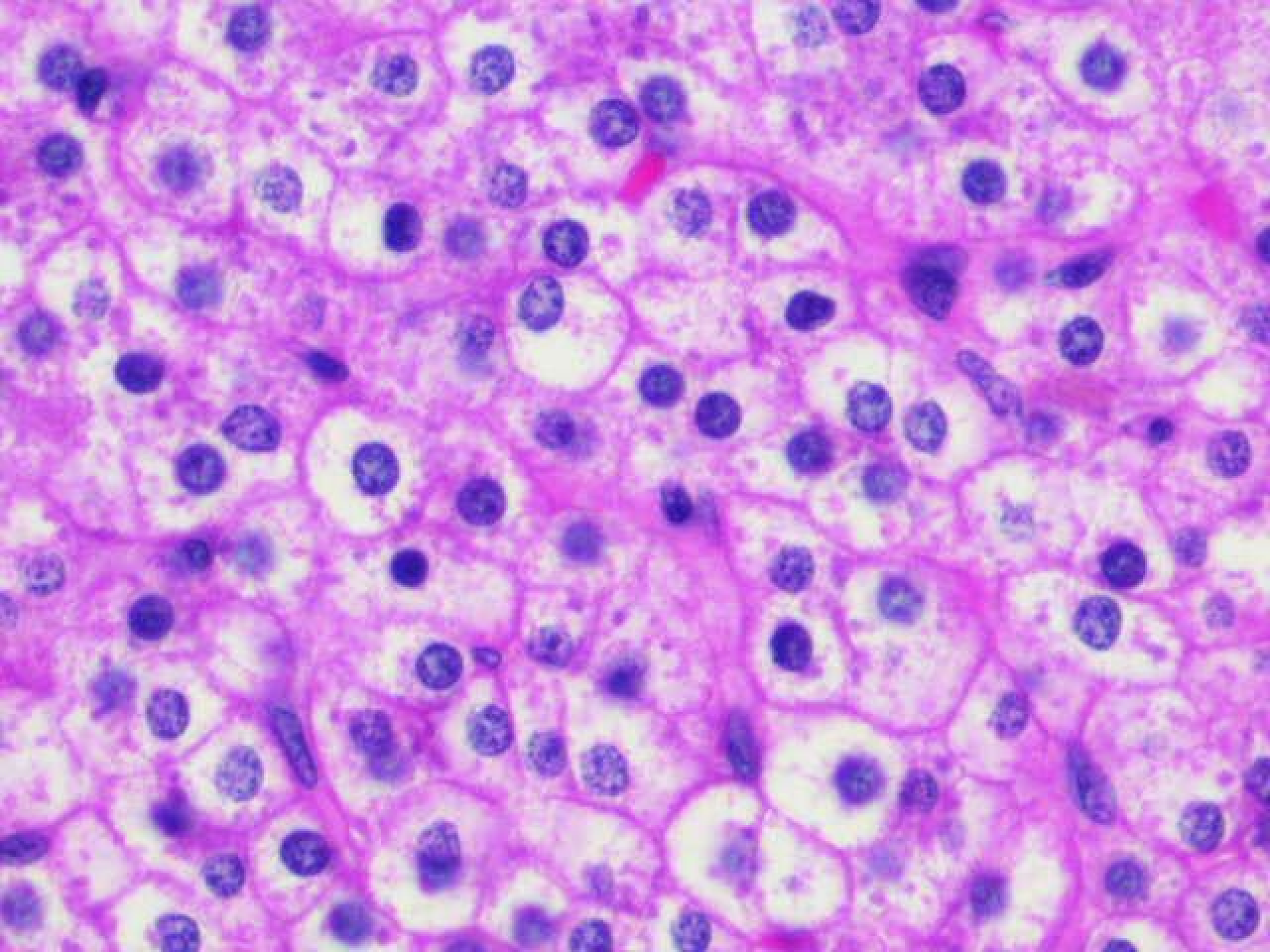

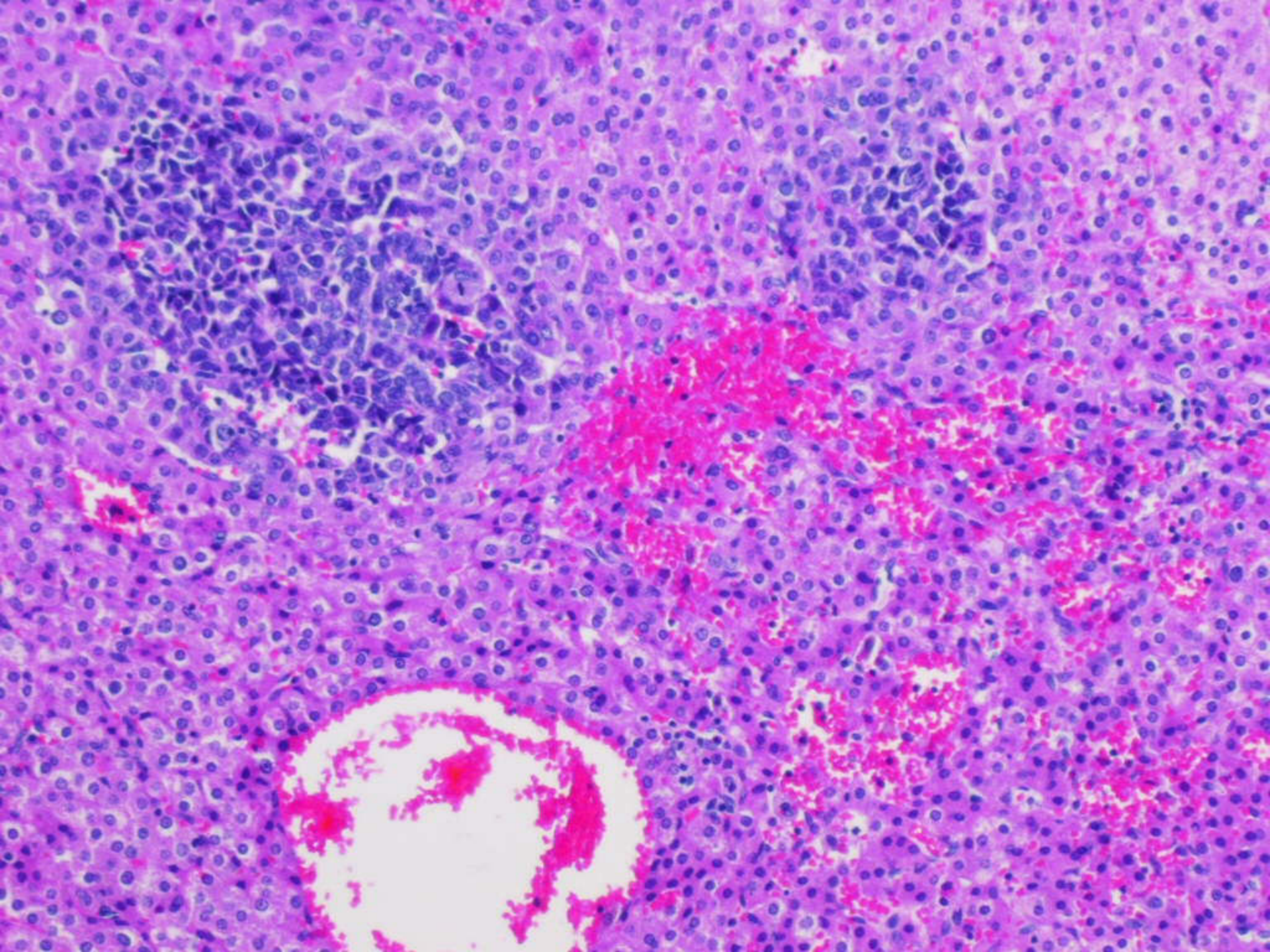

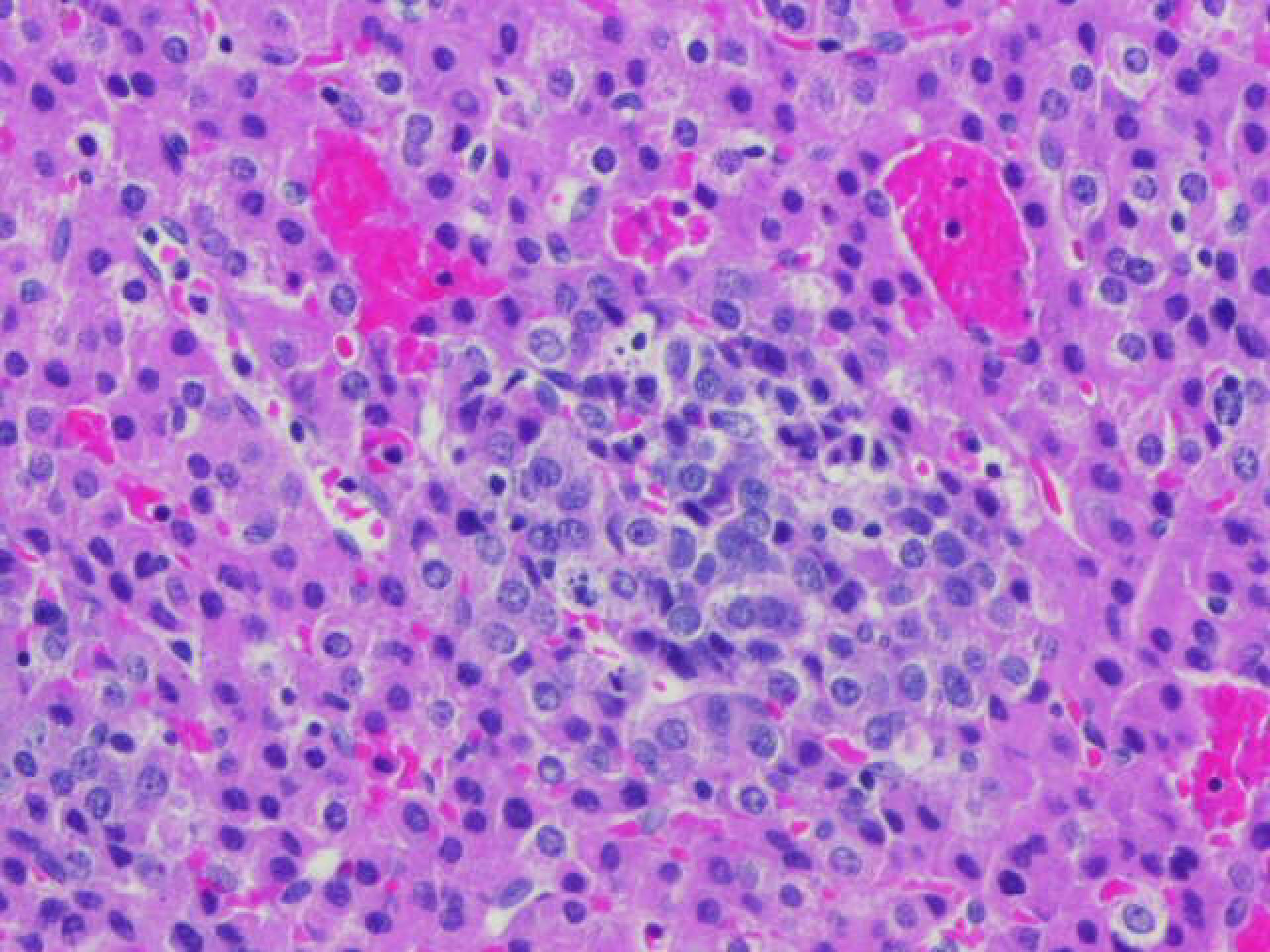

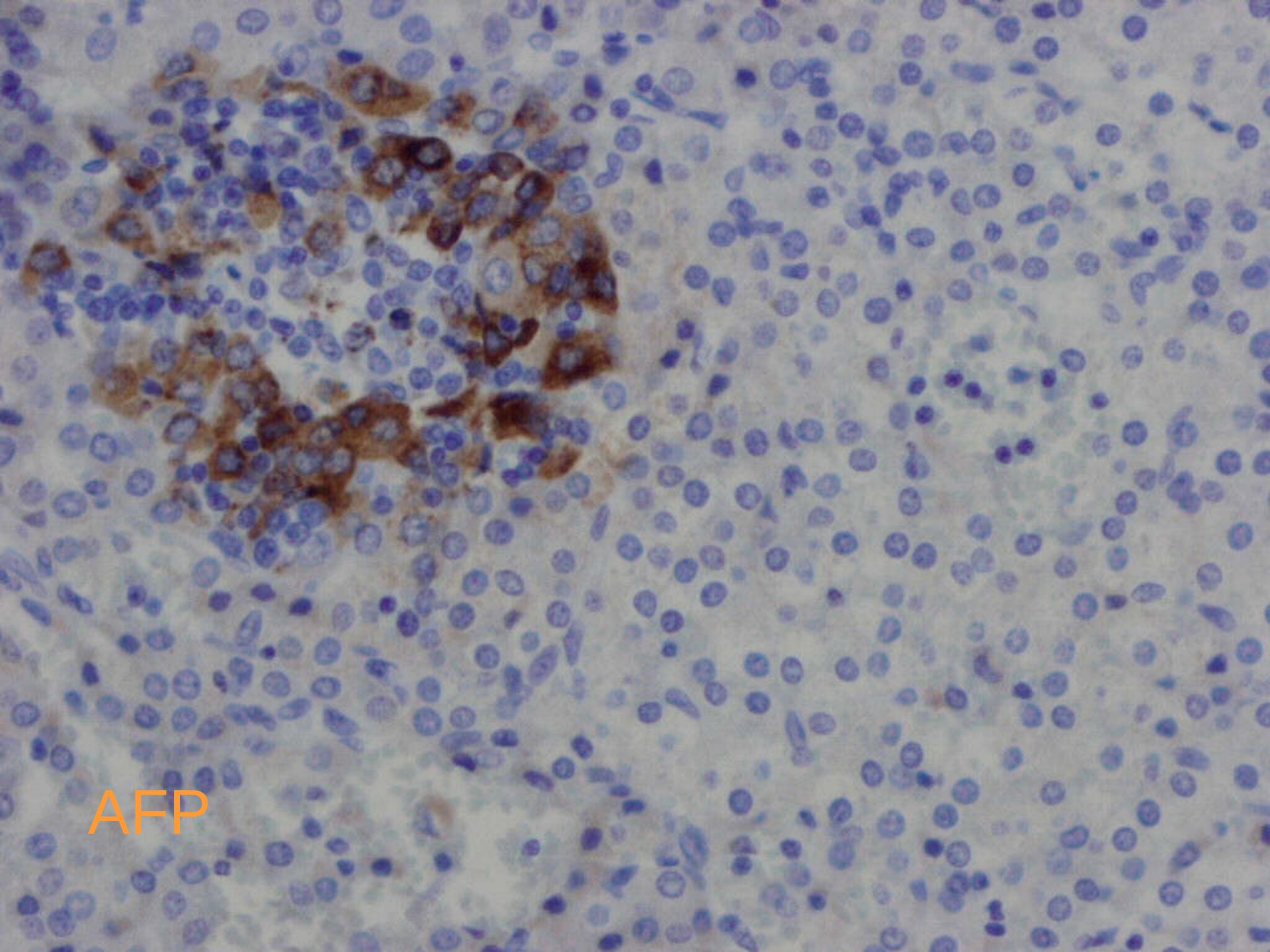
AFP

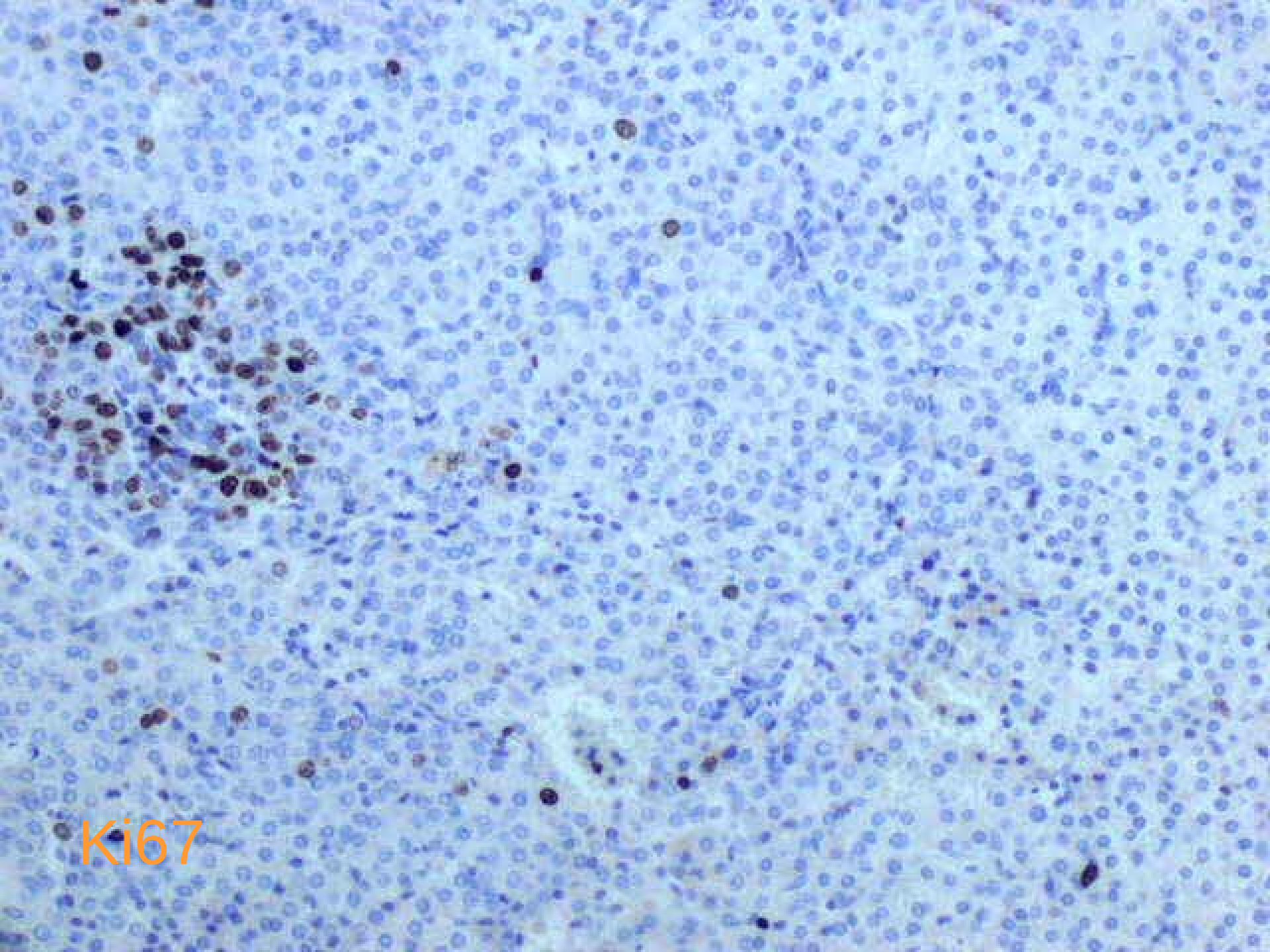
Ki67

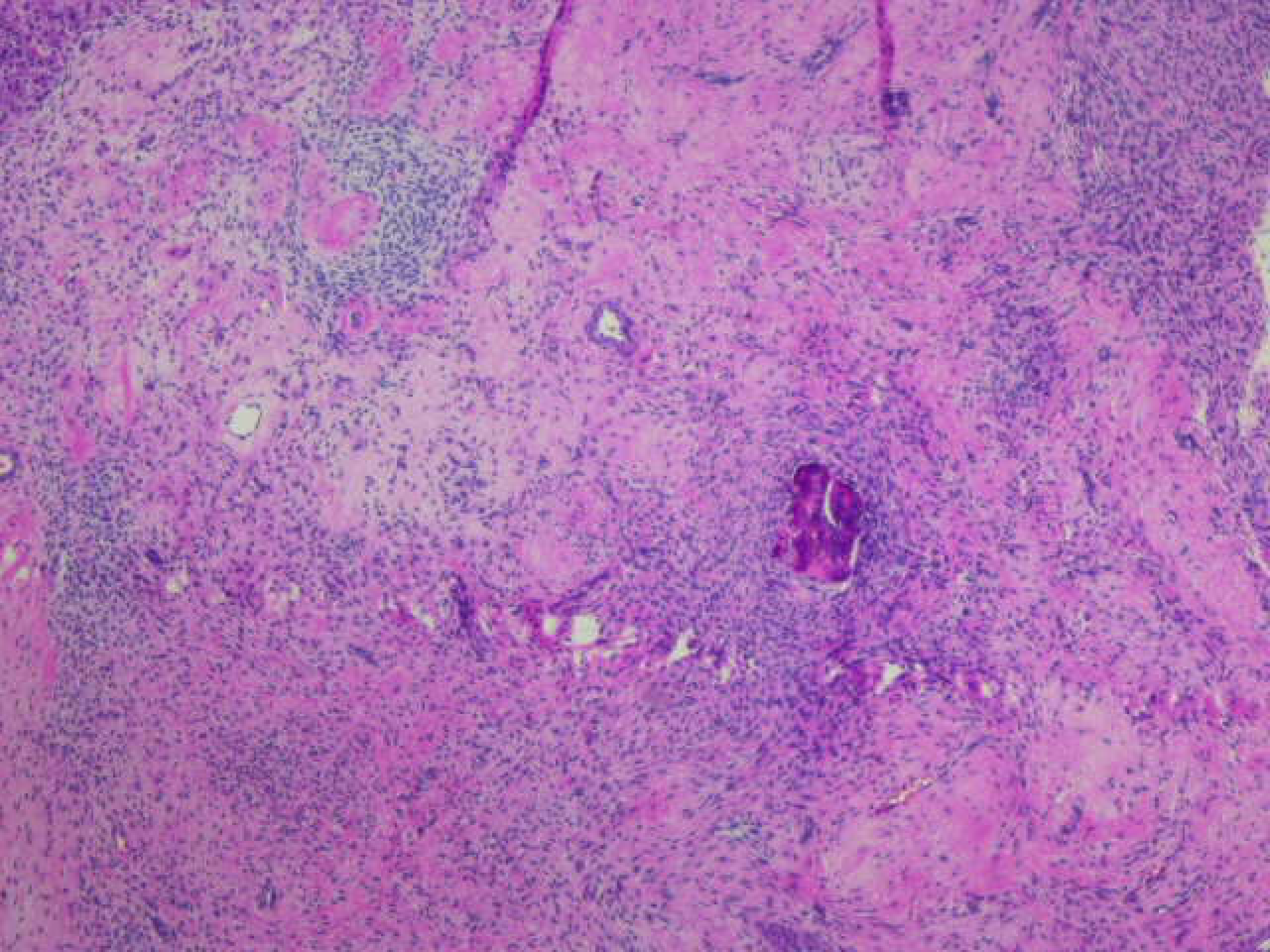

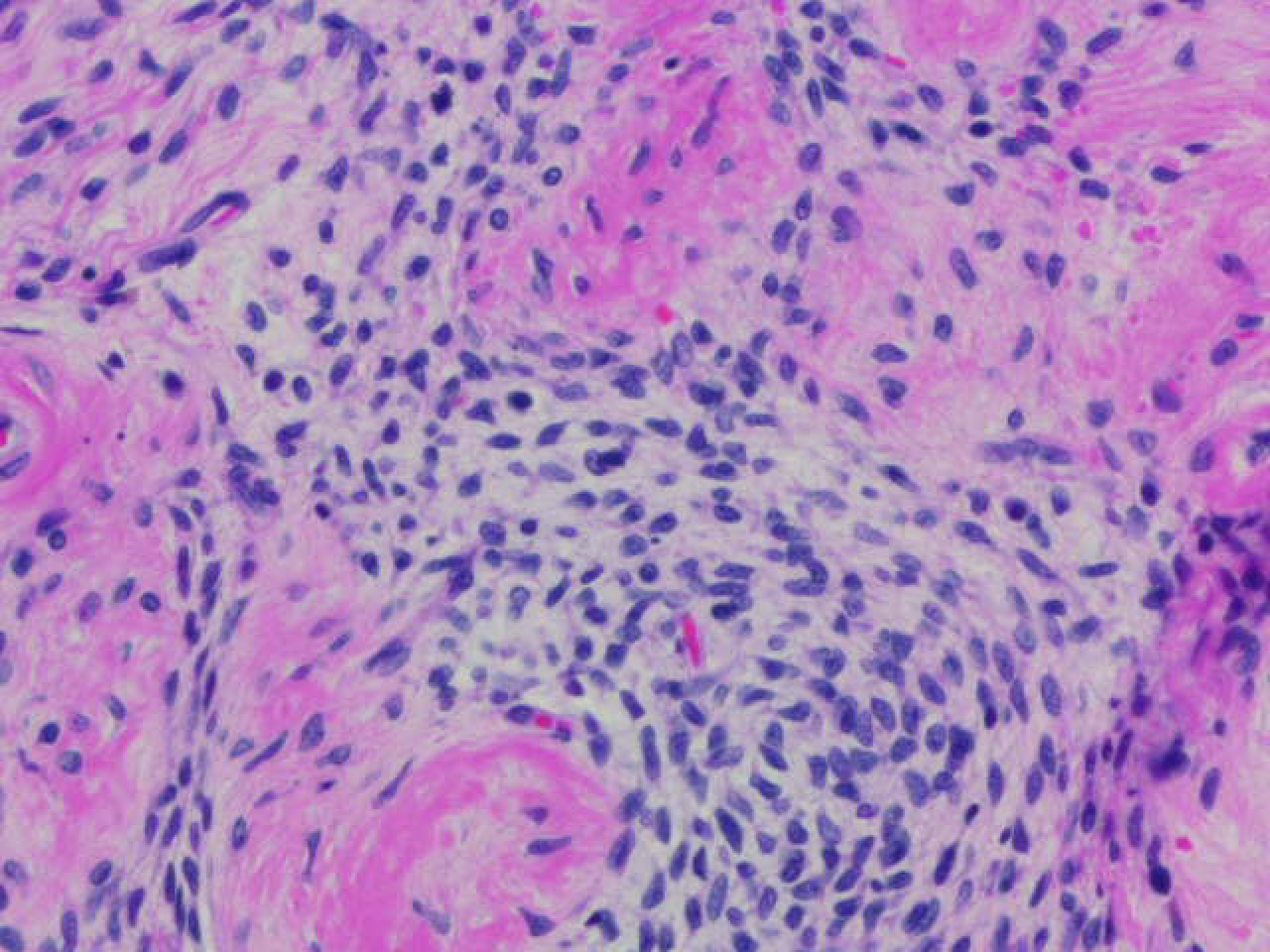

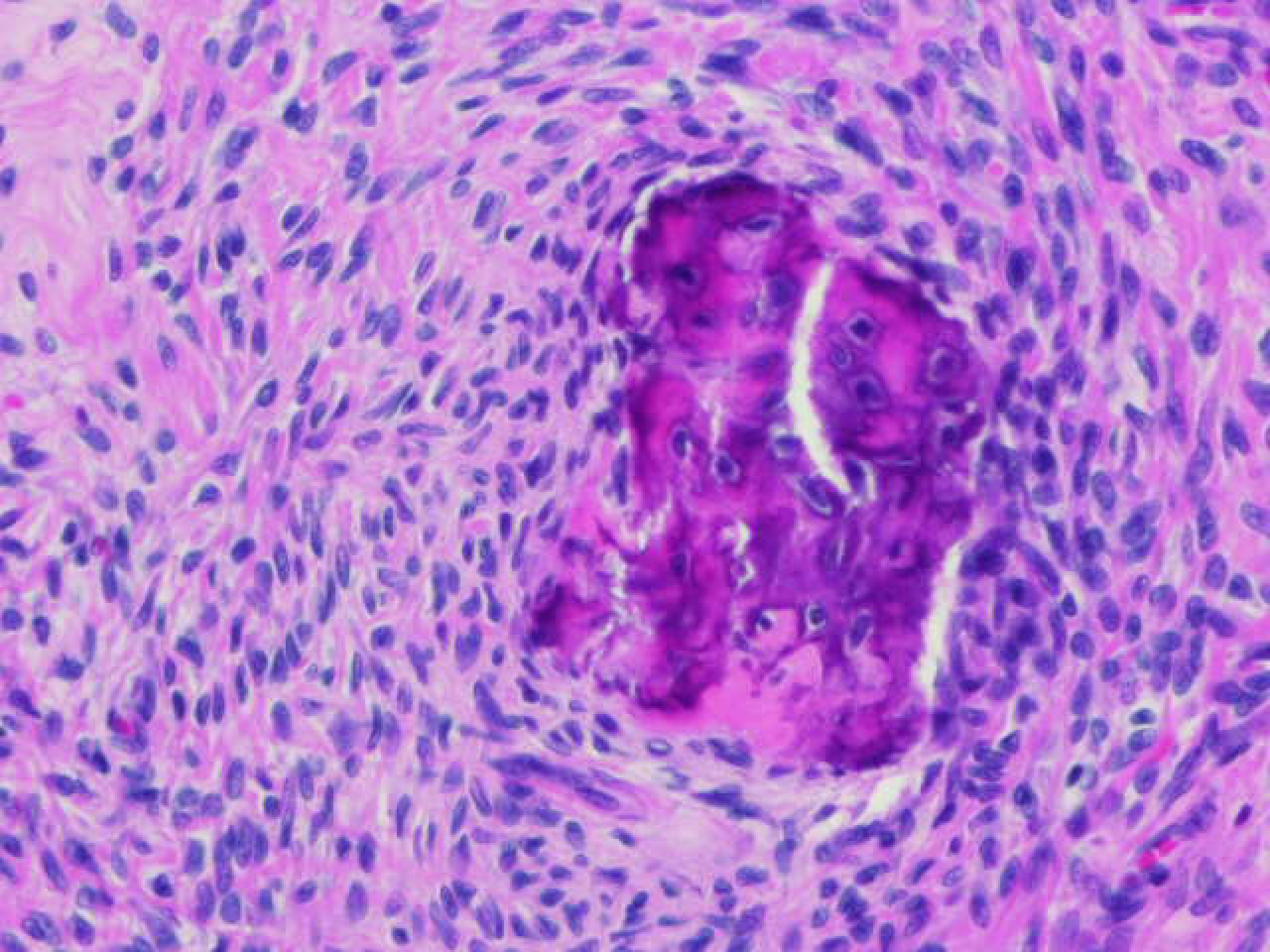

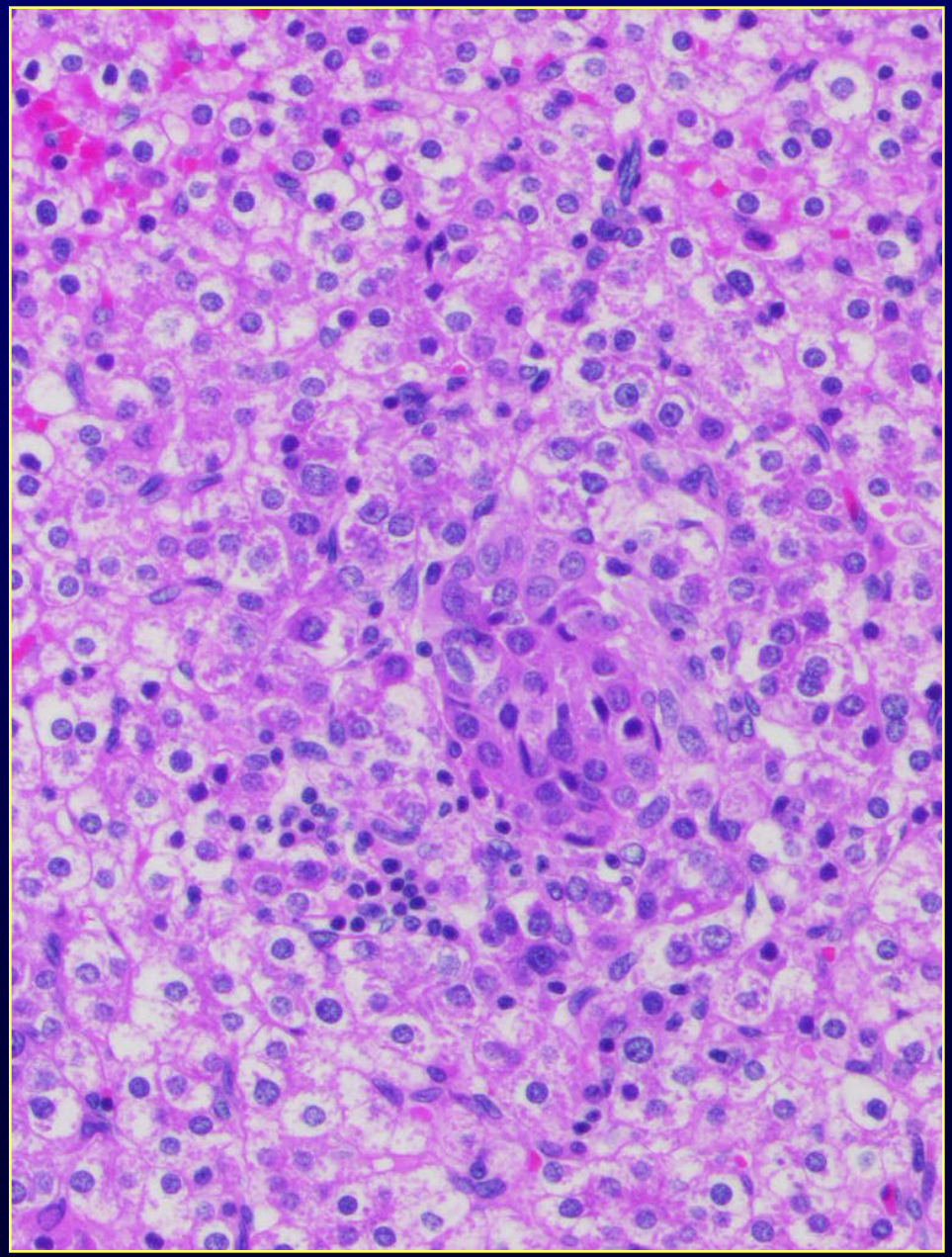

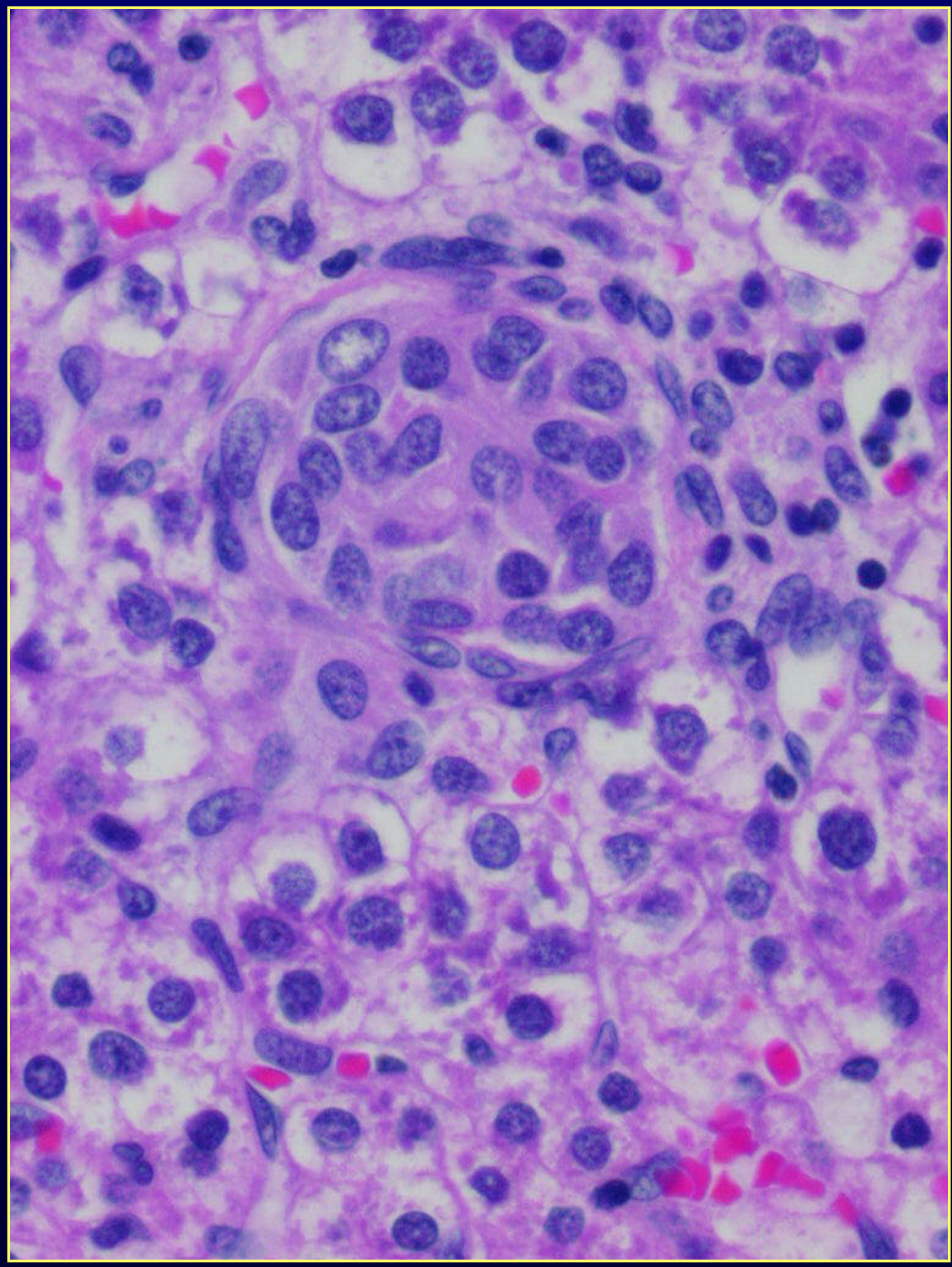

Hepatoblastoma

Mixto (epitelial y mesenquimal)

Tipo fetal (1% embrionario)

Hepatoblastoma

- Tumor maligno embrionario hepático más frecuente en niños.
- Predominio masculino (1,5:1 - 2:1).
- AFP elevada en el 90%.
- Patrones histológicos: epitelial (fetal,fetal y embrionario, macrotrabecular y de célula pequeña) y mixto epitelial/mesenquimal.

Hepatoblastoma

- QT reduce el tamaño en el 85% de casos
- Metástasis: pulmón, hueso, SNC, ovarios y ojos.
- 1/3 anomalía congénita, síndrome o tumor infantil.
- Mal pronóstico: <1 año, tamaño, afectación de estructuras vitales, tipo célula pequeña o macrotrabecular.