112 REUNIÓN TERRITORIAL DE LA SEAP-CV

PATOLOGÍA MAMARIA

Arnau Mompel (R-2), Mª Oliva Álvarez (R-3), Laura Heredia, Jesús Jaramillo (R-1), Isabel Valencia (R-4), María Cabezas, Encarna Andrada.

Servicio de Anatomía Patológica
Hospital General Universitario de Elche

DATOS CLÍNICOS

- PACIENTE MUJER DE 78 AÑOS
- ANTECEDENTES DE:
  - CARCINOMA DE MAMA IZQUIERDA (1991)
    - ESTADIO I , PRÓTESIS BILATERALES (2000)
  - MELANOMA (1996)
    - CLARK III, BRESLOW 1.5mm
  - ADENOCARCINOMA DE RECTOSIGMA (2013)
    - pT2

SEGUIMIENTO ONCOLÓGICO

- APARICIÓN DE ADENOPATÍAS AXILARES DERECHA E IZQUIERDA (2017)

  - BIOPSIA: SIN EVIDENCIA DE MALIGNIDAD

- CONTRACTURA DE CÁPSULA PERIPROTÉSICA DE MAMA IZQUIERDA (2018)

  - CÁPSULA FIBROSA CON ÁREAS DE NECROSIS E INFLAMACIÓN

- PERSISTENCIA DE ADENOPATÍAS AXILARES DERECHAS E IZQUIERDAS Y APARICIÓN DE NUEVAS ADENOPATÍAS EN REGIÓN INFRACLAVICULAR DERECHA (2019)

  - SE REALIZA NUEVAS BIOPSIAS:

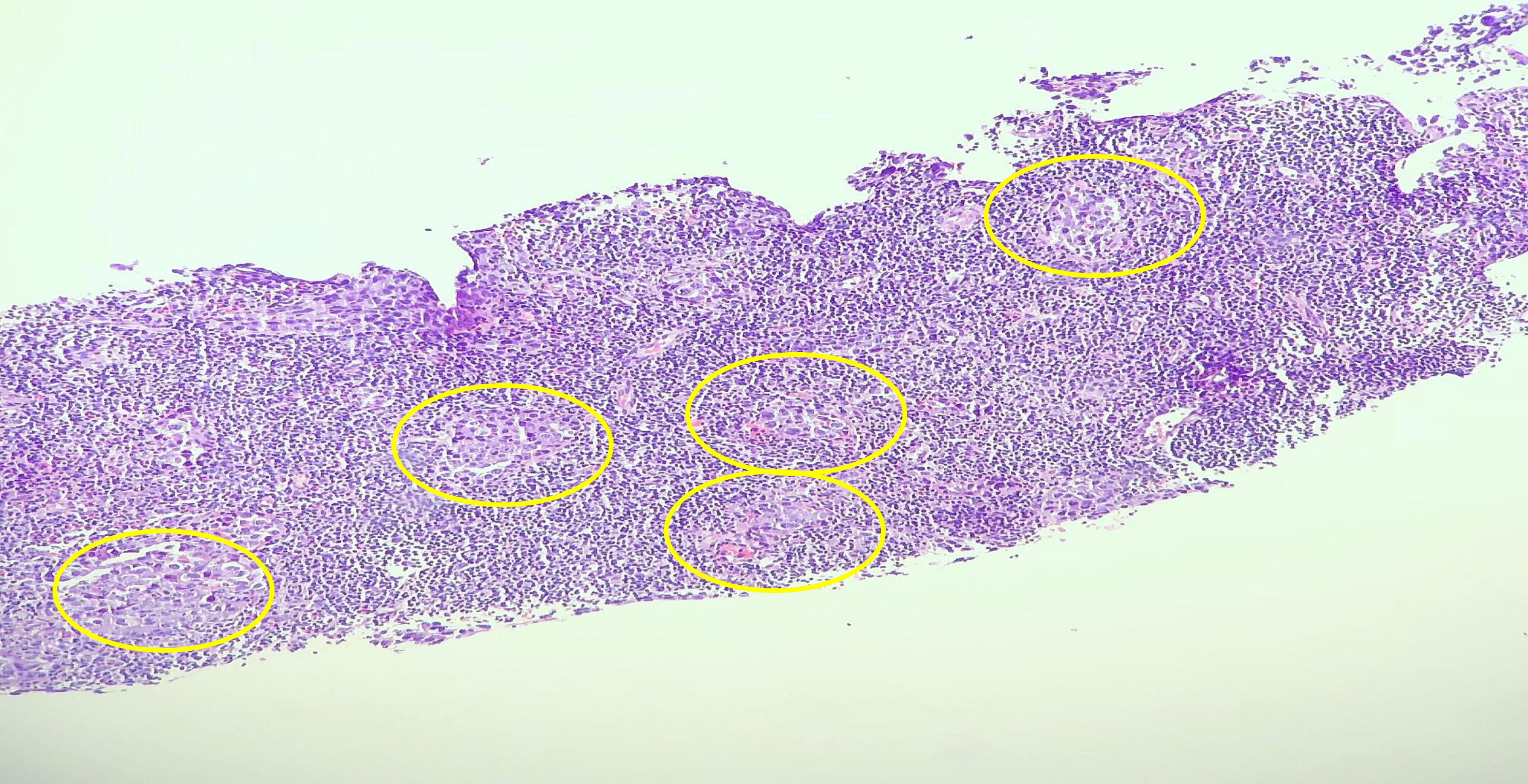

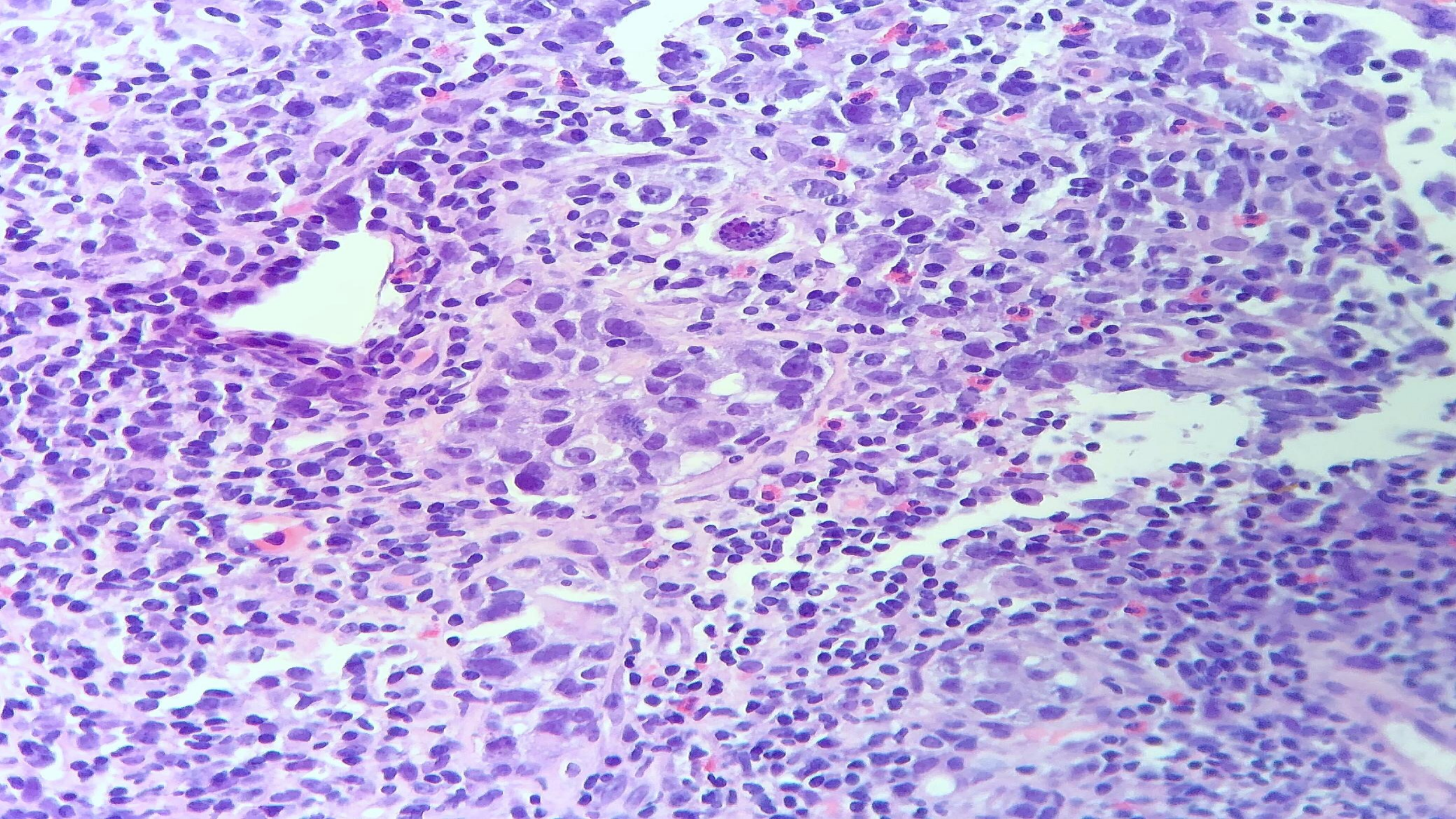

TÉCNICAS IHQ

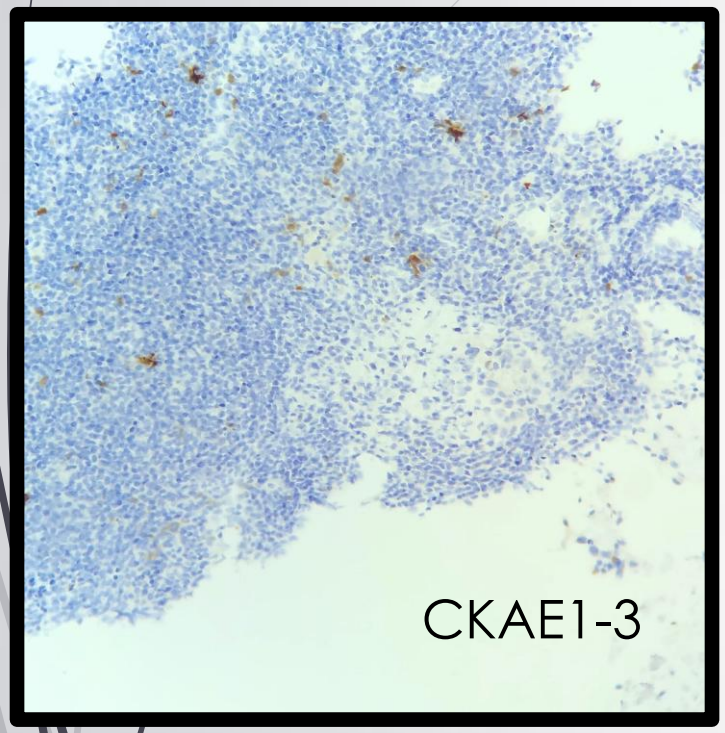



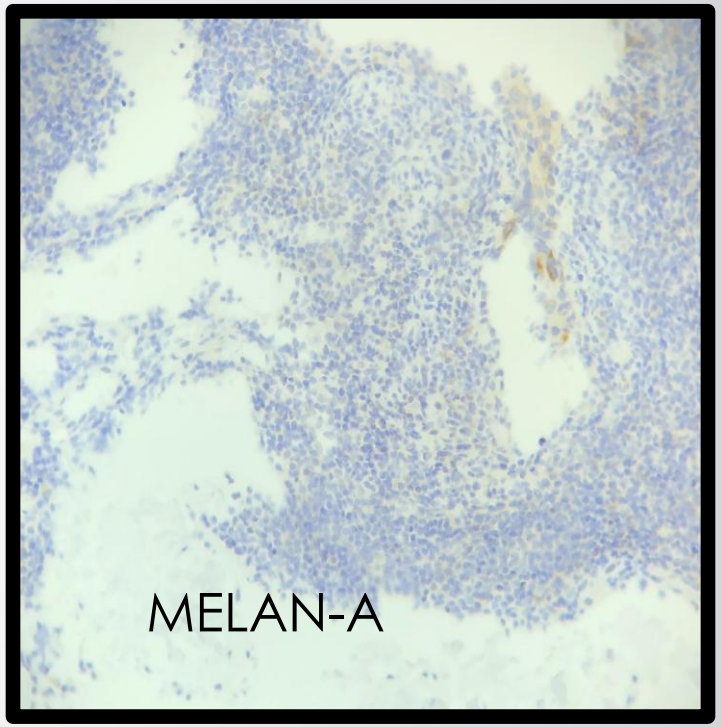

TÉCNICAS IHQ

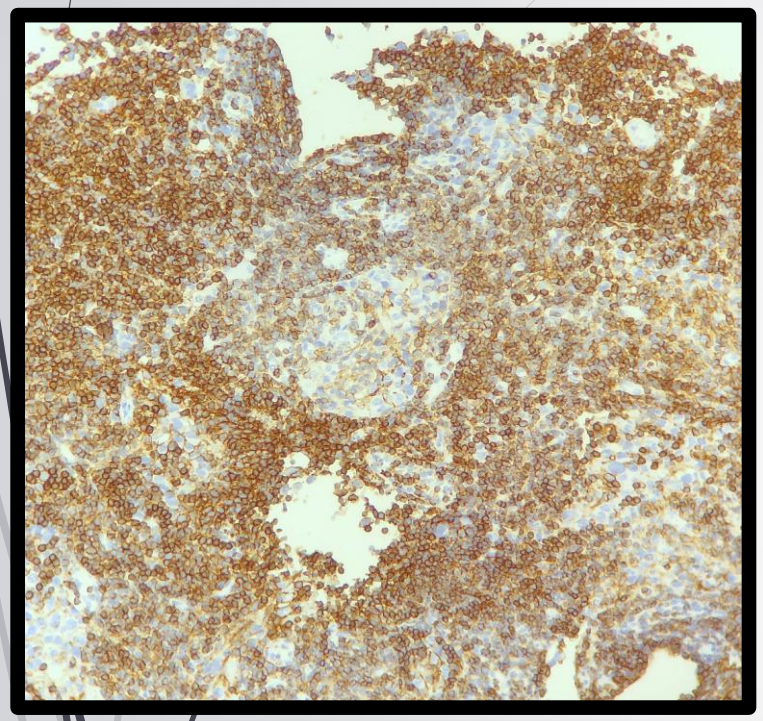

CD45 (LCA)

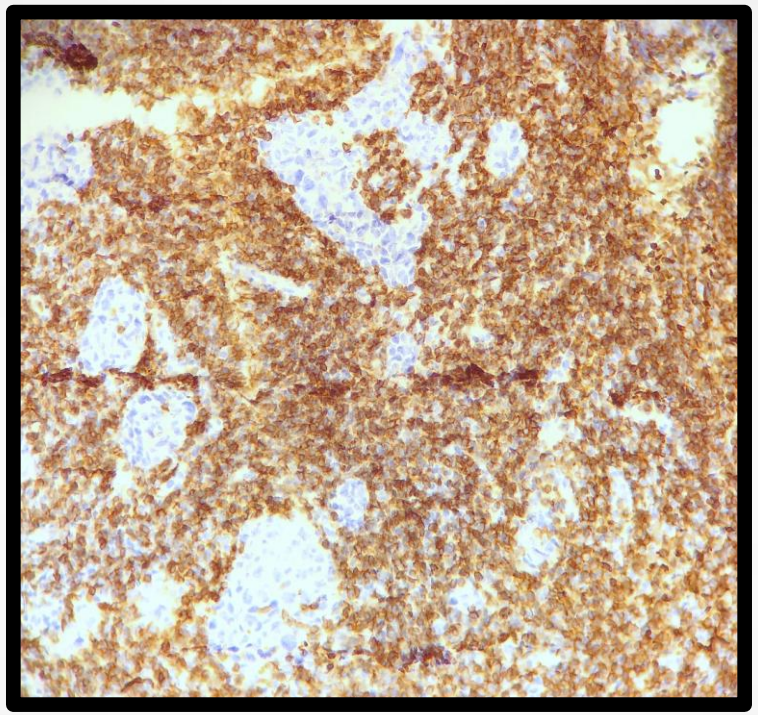

CD3

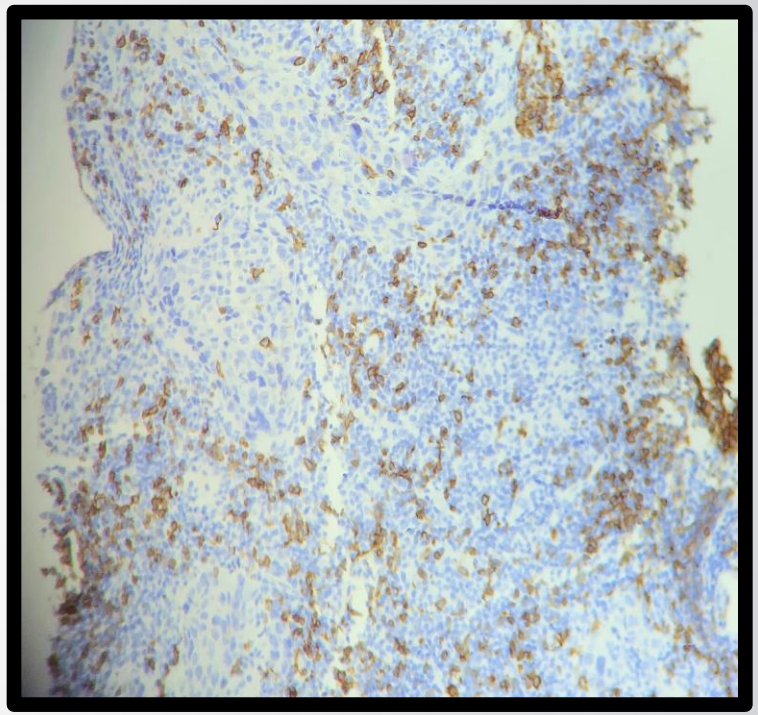

CD20

EN ESTE PUNTO

- ESTIRPE LINFOIDE
- MORFOLOGÍA EPITELIOIDE
- NIDOS SÓLIDOS
- ADENOPATÍAS AXILARES
- CONTRACTURA CAPSULAR DE PRÓTESIS MAMARIA

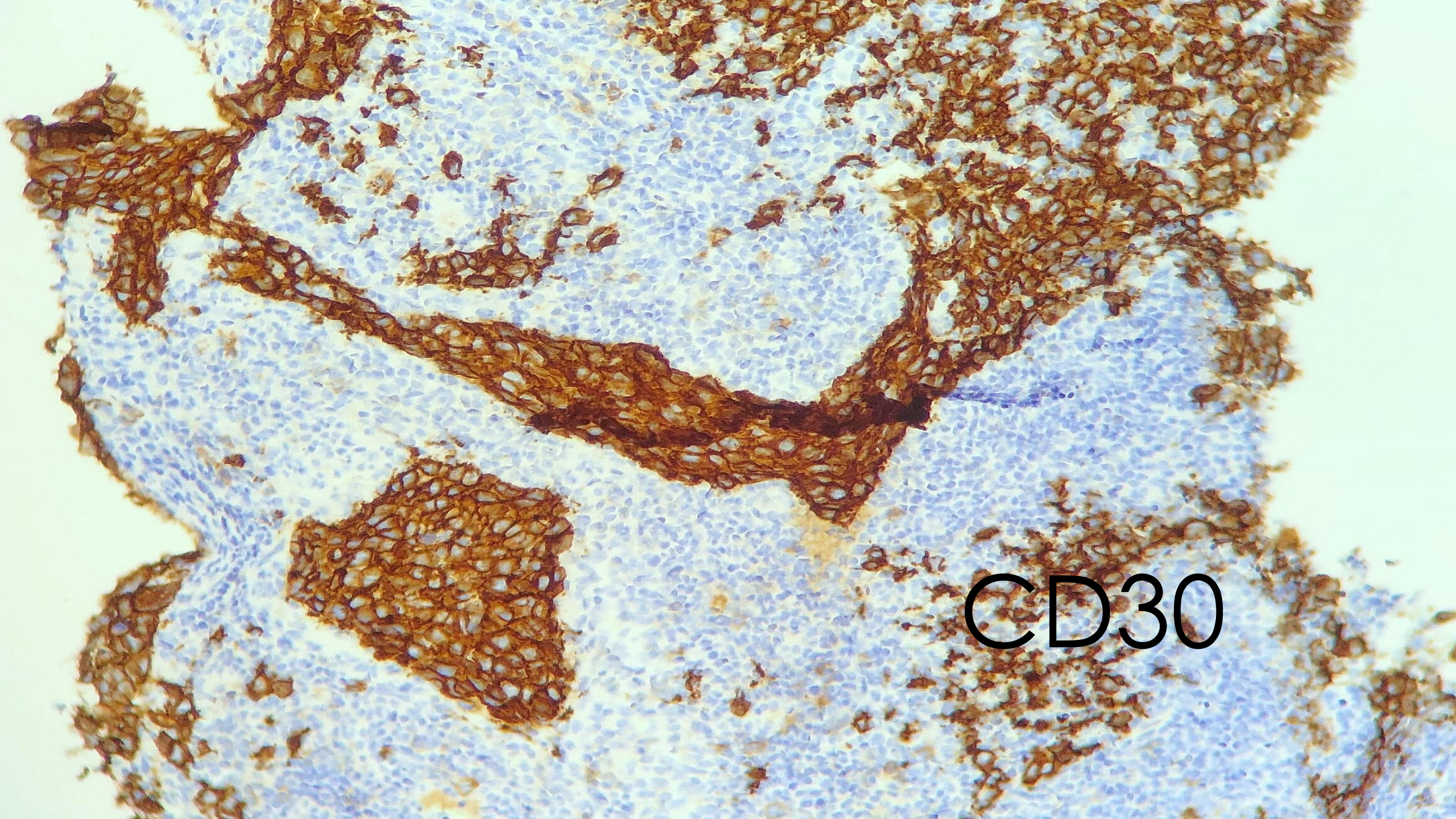
CD30

TÉCNICAS IHQ

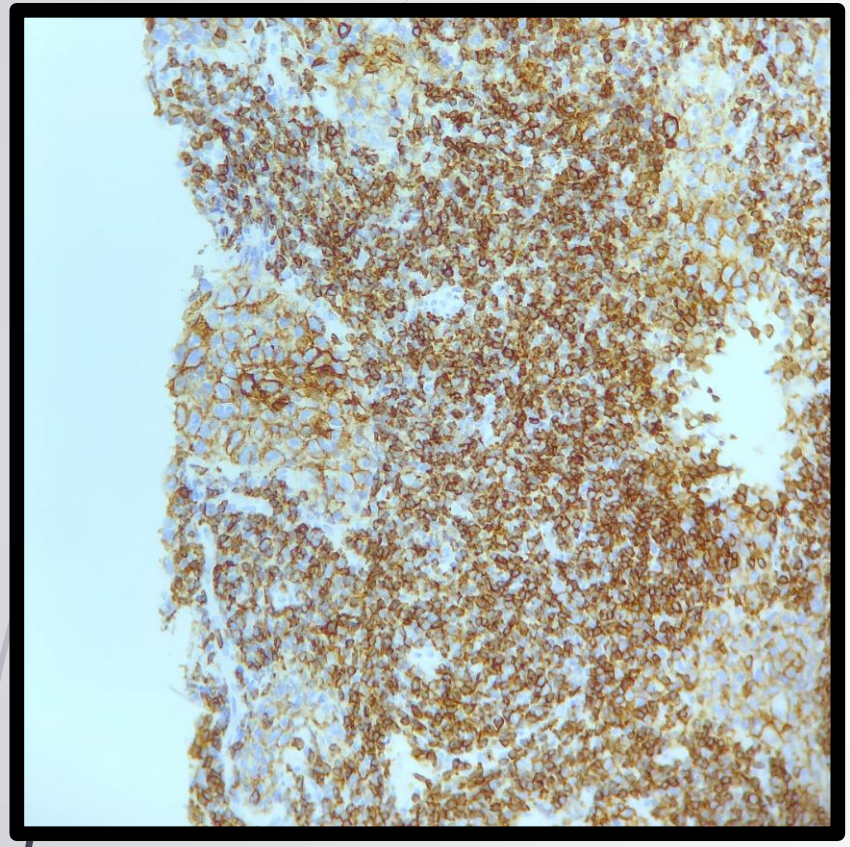

CD43

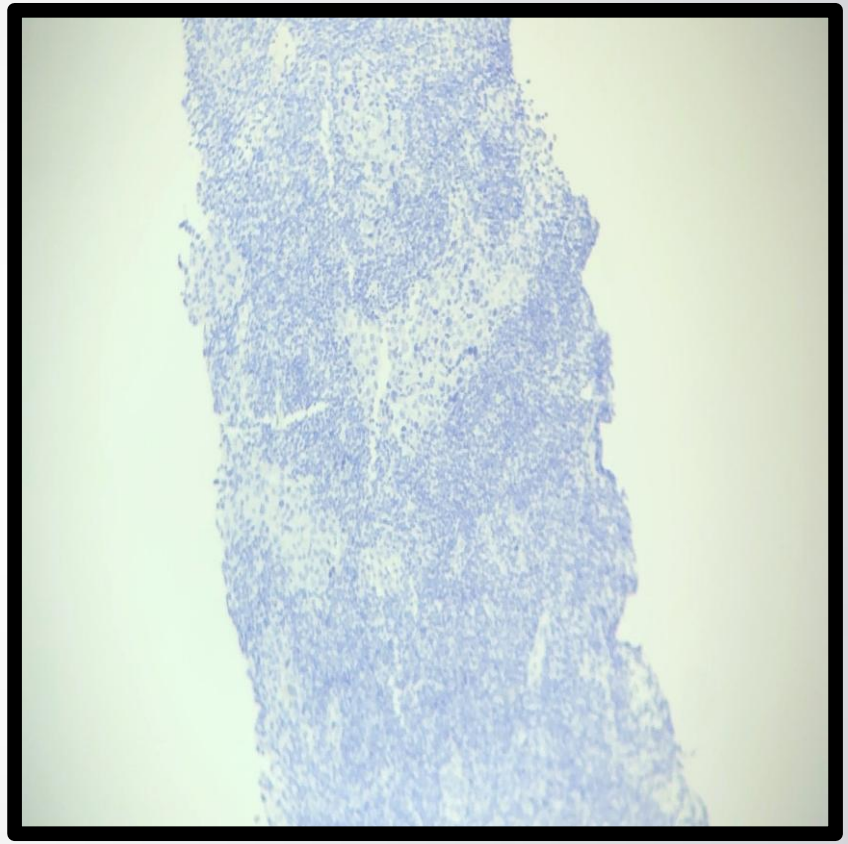

ALK

INMUNOHISTOQUÍMICA	
PanCK	NEGATIVO
S-100	NEGATIVO
Melan A	NEGATIVO
CD45 (LCA)	POSITIVO
CD3	NEGATIVO
CD20	NEGATIVO
CD30	POSITIVO
CD43	POSITIVO
ALK	NEGATIVO
BCL6	POSITIVO
EMA	POSITIVO
PAX 5	NEGATIVO
CD68	NEGATIVO
CD34	NEGATIVO

Revisar biopsias previas de la paciente

- Se realiza CD30 en:

ADENOPATÍAS AXILARES DERECHA E IZQUIERDA (2017)

- NEGATIVAS

CÁPSULA PERIPROTÉSICA DE MAMA IZQUIERDA (2018)

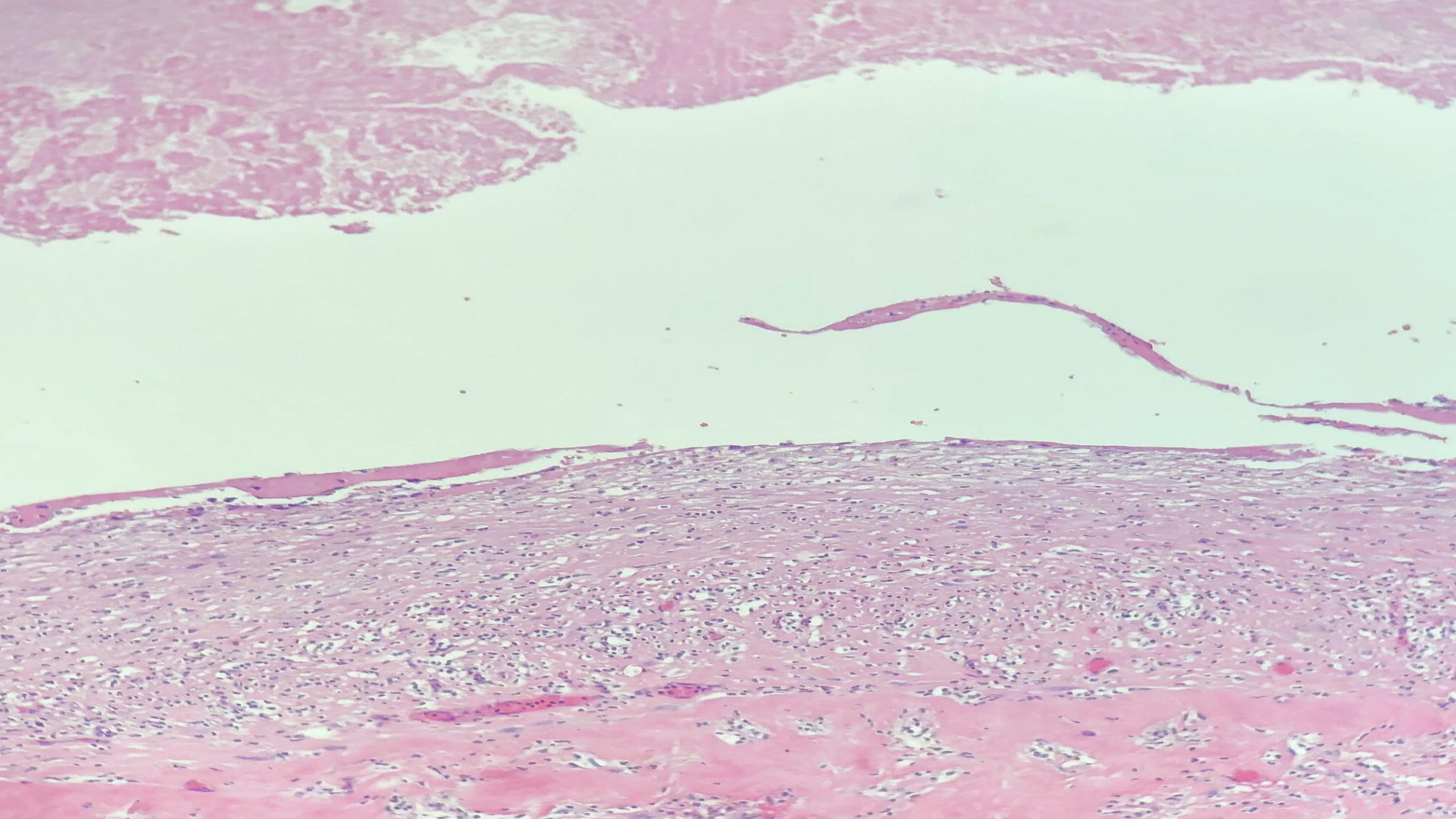

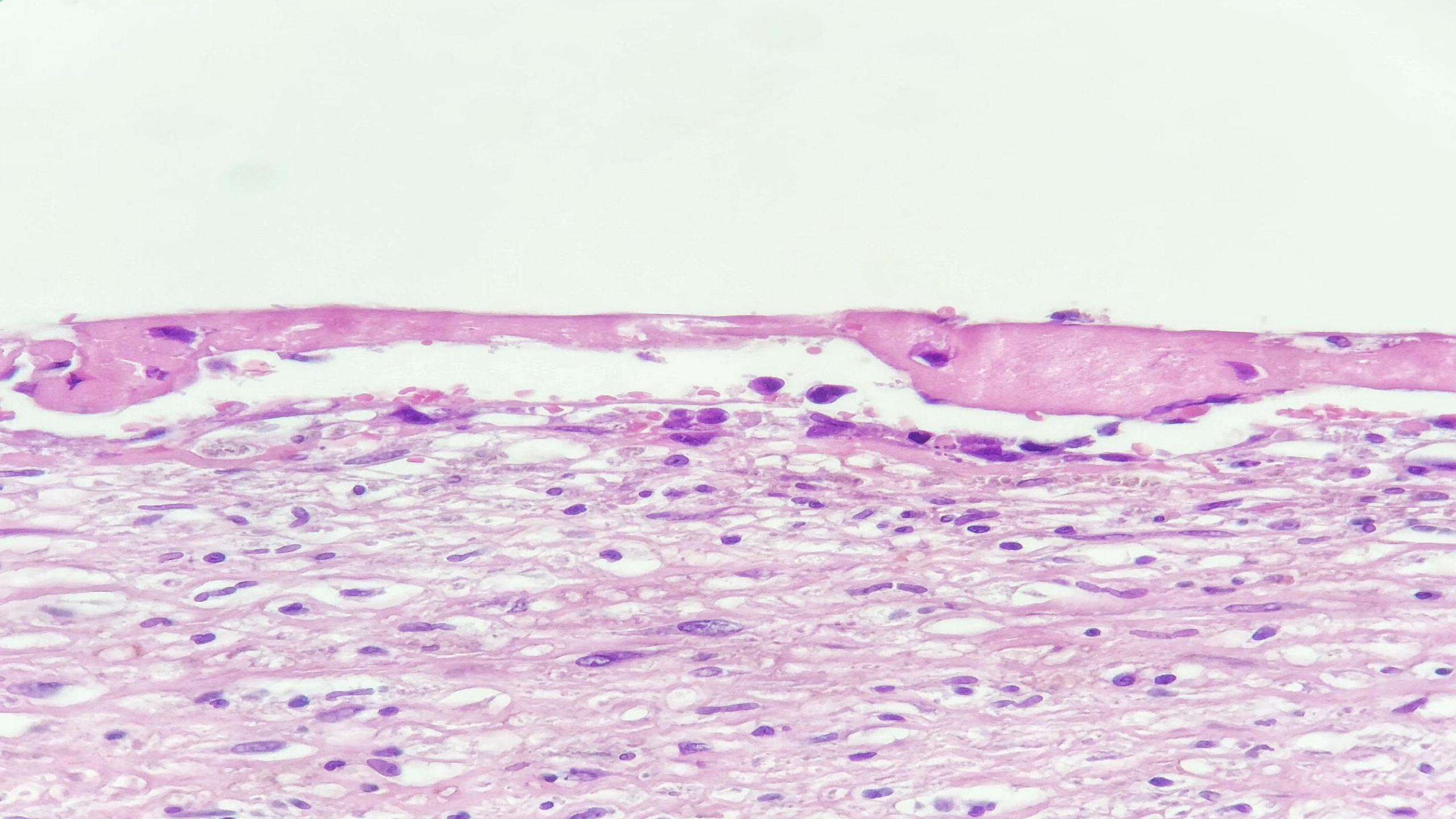

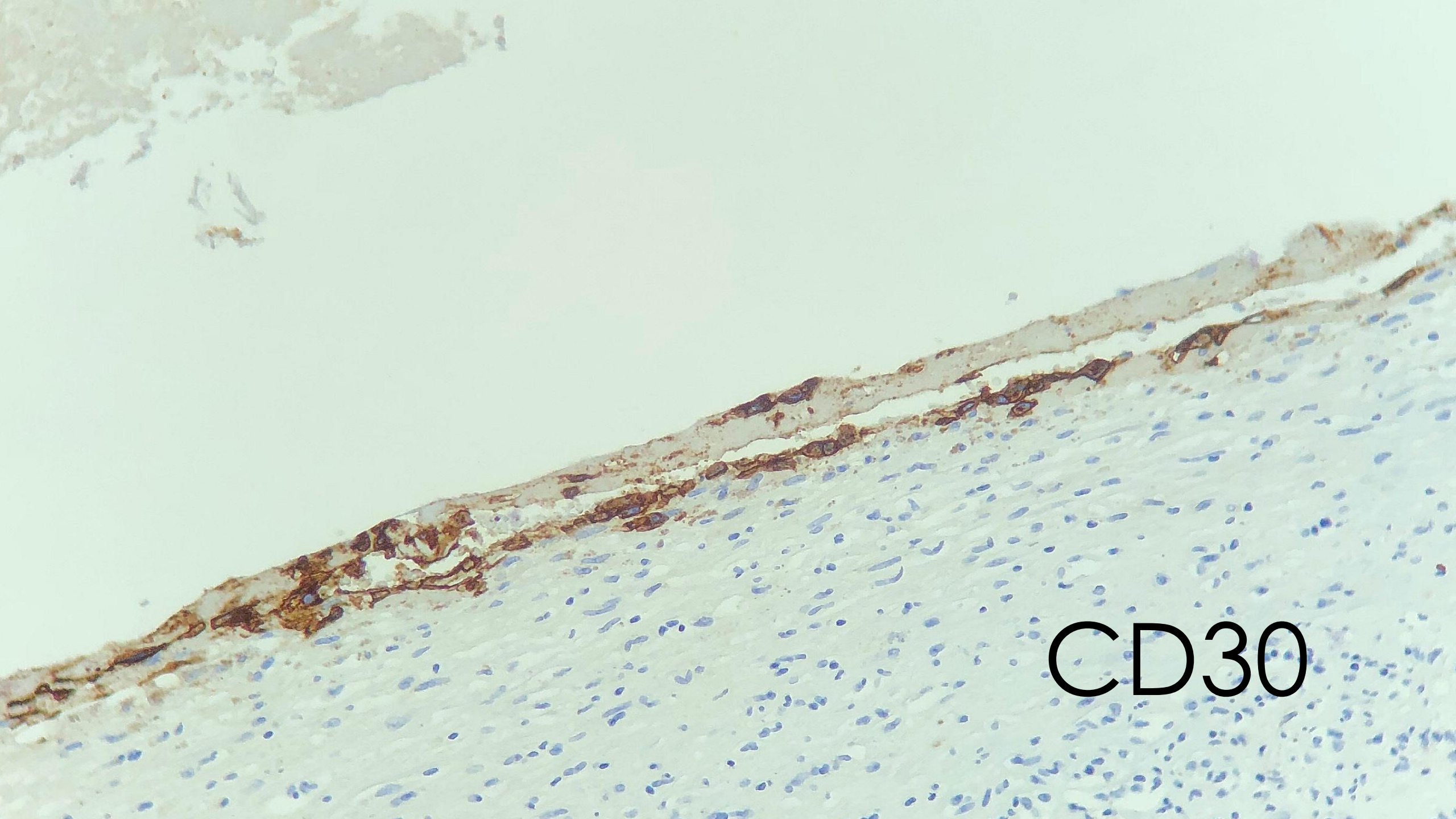
CD30

TABLE 3. Differential Diagnosis of Lymphoproliferative Lesions Occurring at Site of Breast Implant

Diagnosis	Silicon Implant	$CD30^+$ Large Cells	Alk-1	Other IHC Markers
Implant-associated ALCL	Always	Many	Negative	Various T-cell markers, EMA
Anaplastic tumor, unknown origin	No*	Anaplastic cells, $CD30^-$	Negative	Keratin, S100, or other markers present
Chronic inflammation	No*	Absent or rare	Negative	Admixture of reactive T and B cells, and histiocytes
Lymphomatoid papulosis	No*	Few to many	Negative	Various T-cell markers
Primary Cutaneous ALCL	No*; predates or occurs in skin remote from implant	Many	Negative	Various T-cell markers, EMA
Systemic ALCL secondary to breast	No*; primary site other than skin	Many	Most positive	Various T-cell markers, EMA
B-cell lymphoma	No*	Occasional in some subtypes	Negative	CD20, Pax5, other B-cell markers
T-cell lymphomas (other than ALCL)	No*	Rare, some subtypes	Negative	Various T-cell markers
Hodgkin lymphoma classic	No*	RS cells and variants	Negative	CD15, Pax5

*Lesion occurs at remote site and in absence of breast implant; occurrence at implant site is considered coincidental.
ALCL indicates anaplastic large cell lymphoma; IHC, immunohistochemical; RS, Reed Sternberg.

DIAGNÓSTICO ANATOMOPATOLÓGICO

LINFOMA T ANAPLÁSICO DE CÉLULAS GRANDES ASOCIADO A IMPLANTES MAMARIOS

Linfoma T anaplásico de célula grande asociado a implante mamario

- Entidad provisional y de nueva introducción (WHO 2017)
- Indistinguible del ALCL ALK-, salvo por la presencia de prótesis mamarias.
- 1/500,000-3,000,000 de mujeres con implantes.
- Edad media 50 años.
- 11 años de intervalo medio.
- NO asociación establecida con el tipo de implante.
- NO asociación establecida con antecedente de cáncer de mama.

FORMA DE PRESENTACIÓN

- Seroma recidivante.
- Tejido fibroso pericapsular.
- Masa.
- Ganglios locorregionales.

TRATAMIENTO

- RETIRADA DE LA PRÓTESIS
- QUIMIOTERAPIA/RADIOTERAPIA

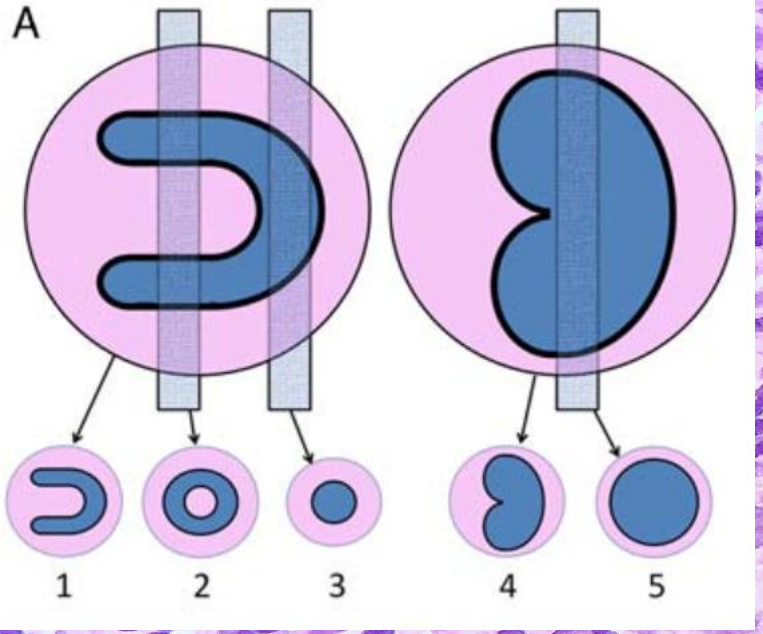

"hallmark cells"

Gracias