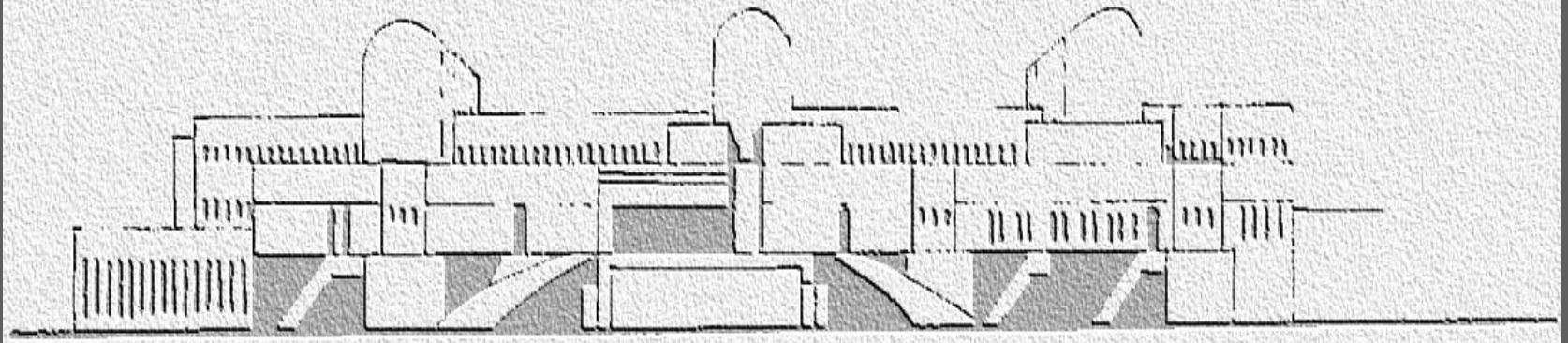

Hospital de la Plana

CASO 1 :

Dr. R.Lázaro, Dra. E. Muñoz,
Dra. M. Palomo y Dra. C. Andrés.

CASOS CLINICOS:

- **Tumor 1:** Mujer de 34 años con dolor abdominal difuso de 1 año de evolución. Tumor en cuerpo de páncreas

- **Tumor 2:** Mujer de 34 años con dos episodios de pancreatitis aguda leve. Tumor en cabeza de páncreas.

1
2
48.1/-8.3
49.5/85.8
0.0/0.0
R
L

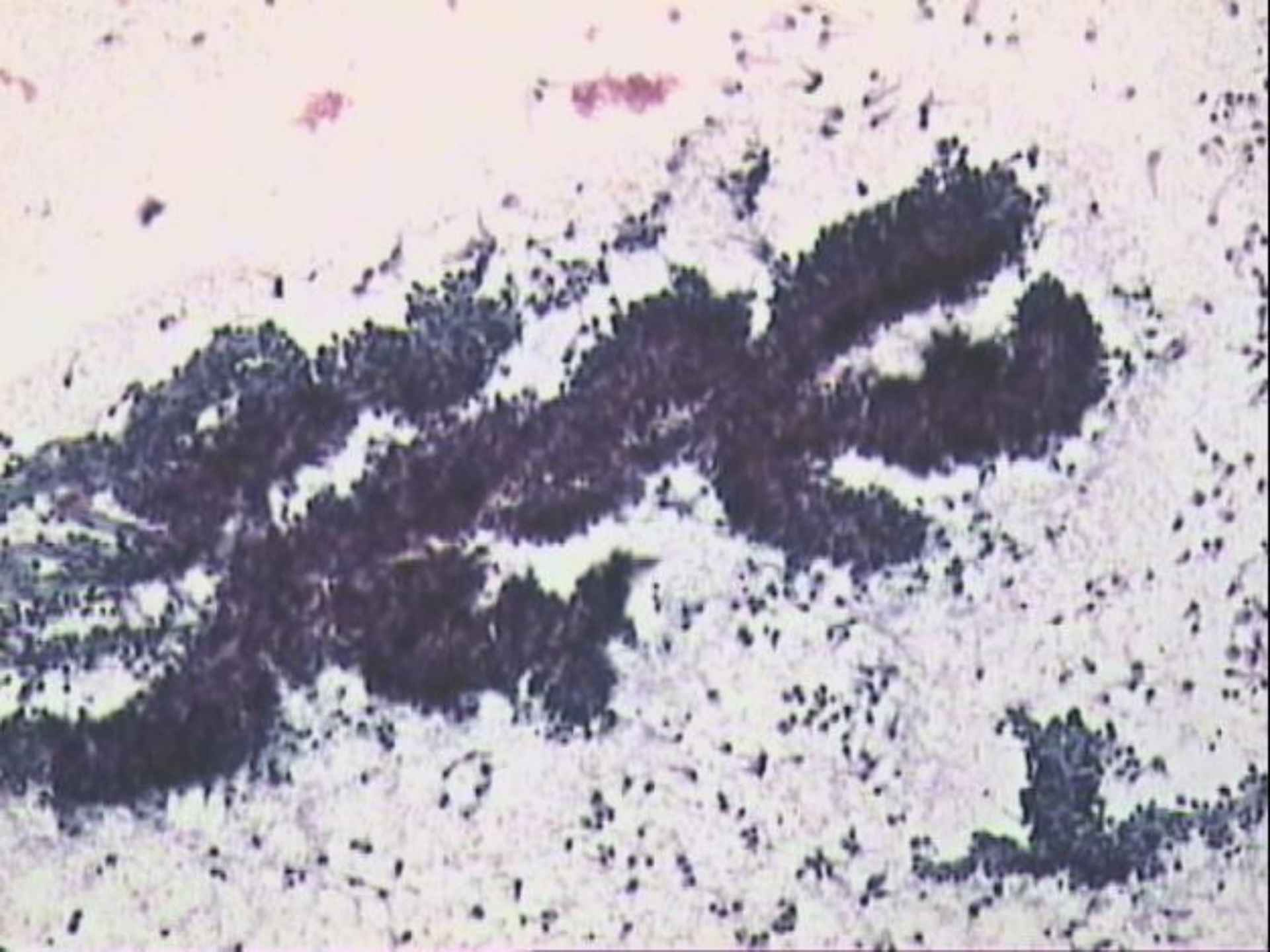

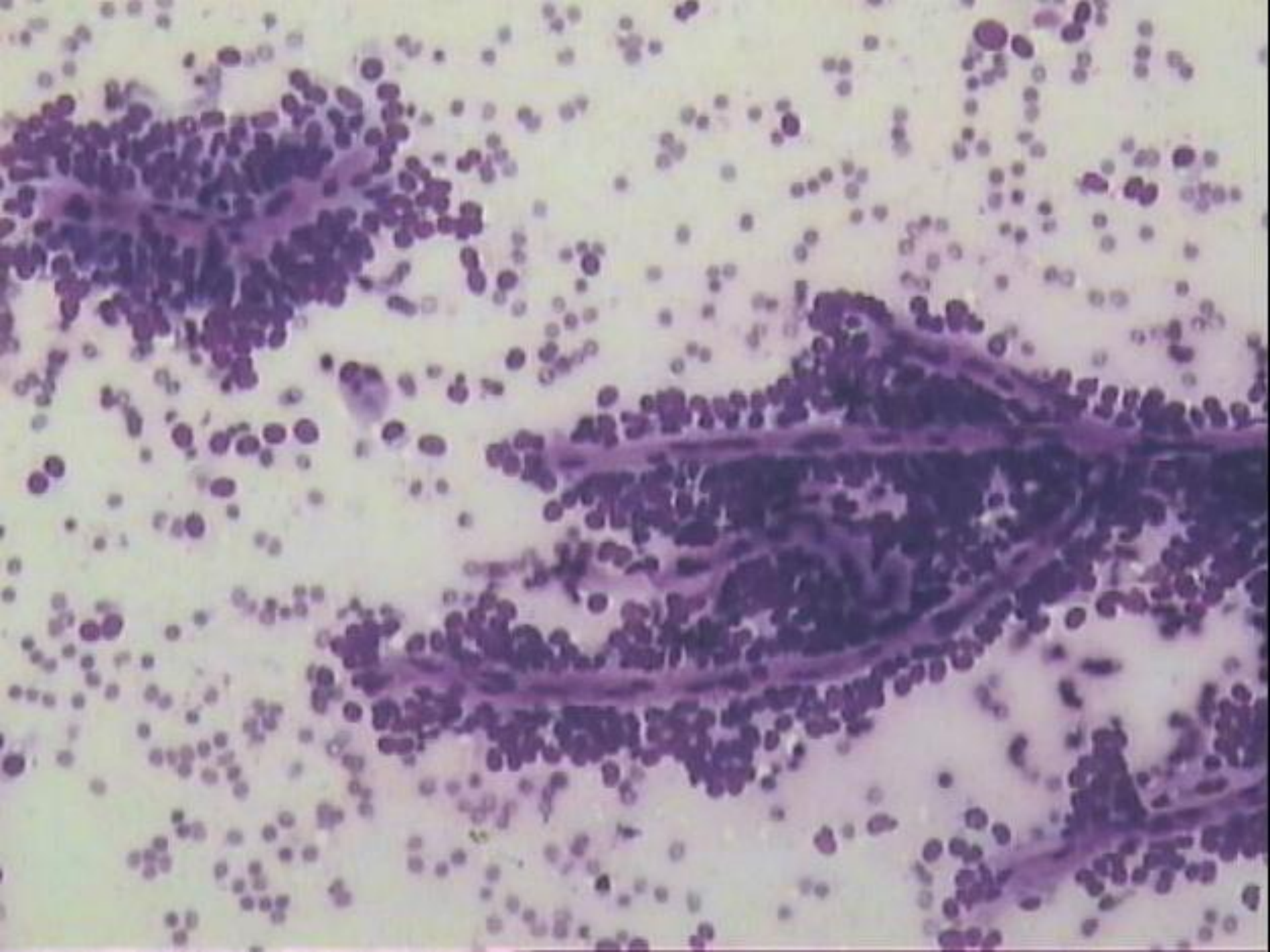

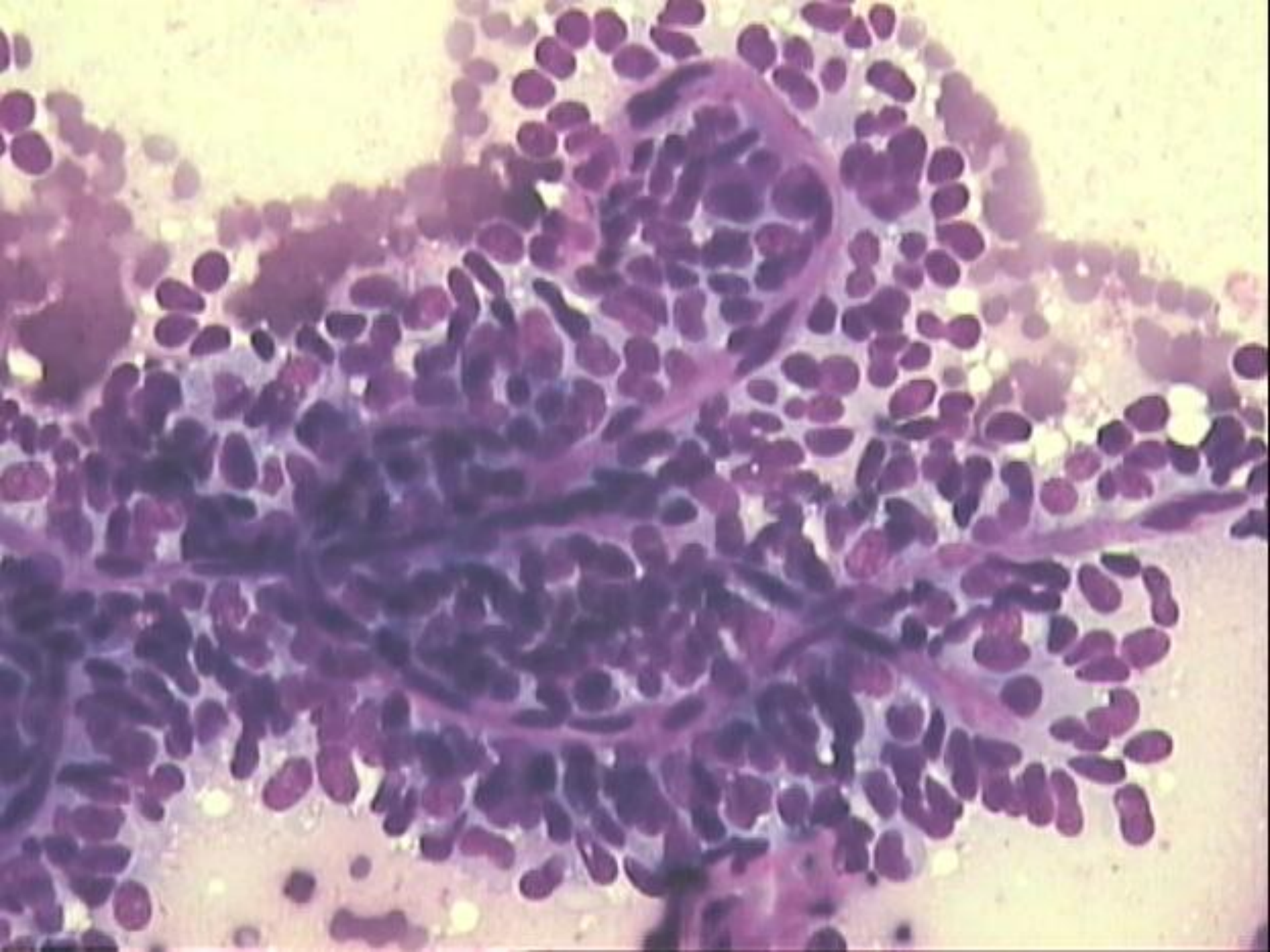

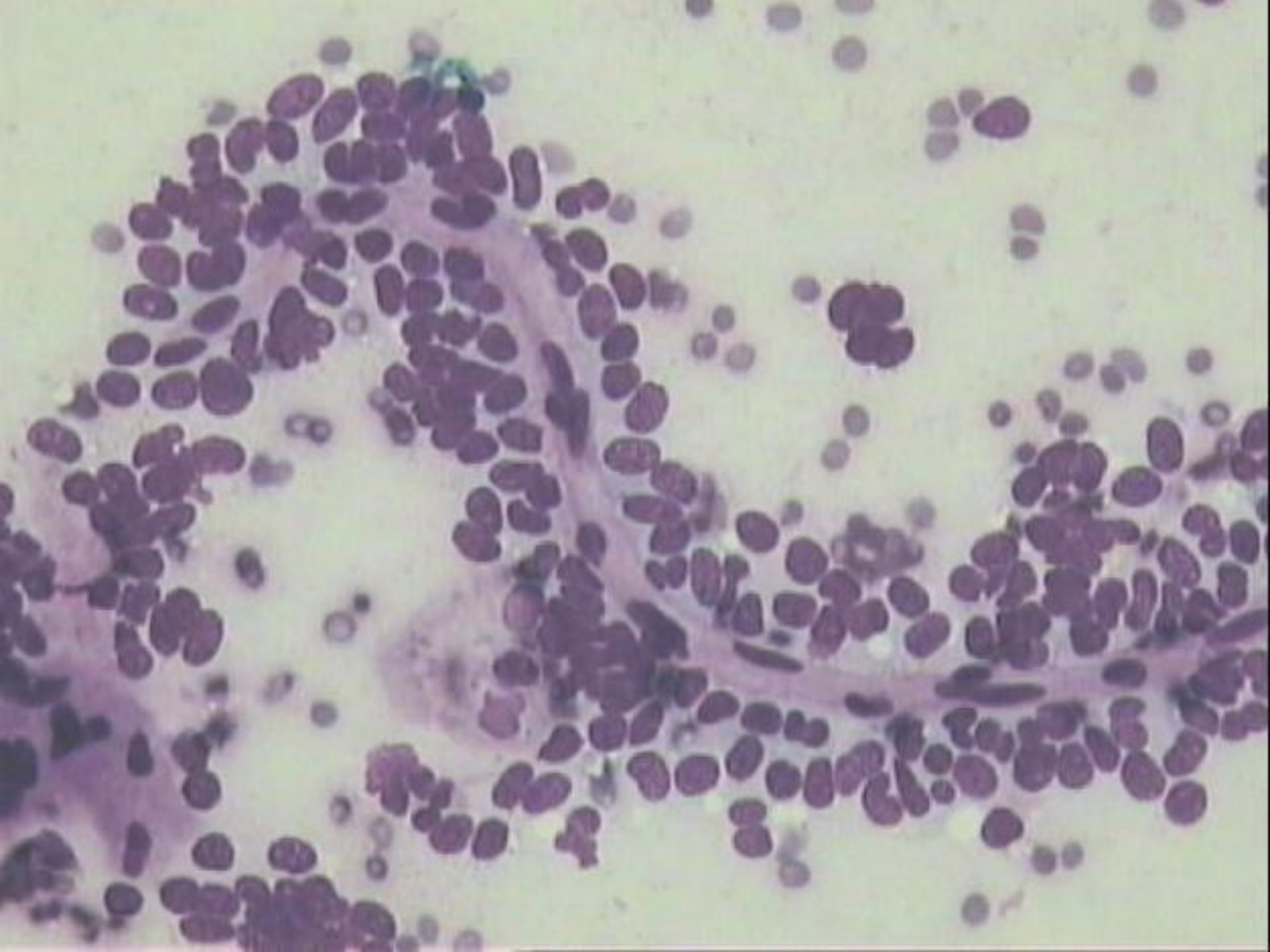

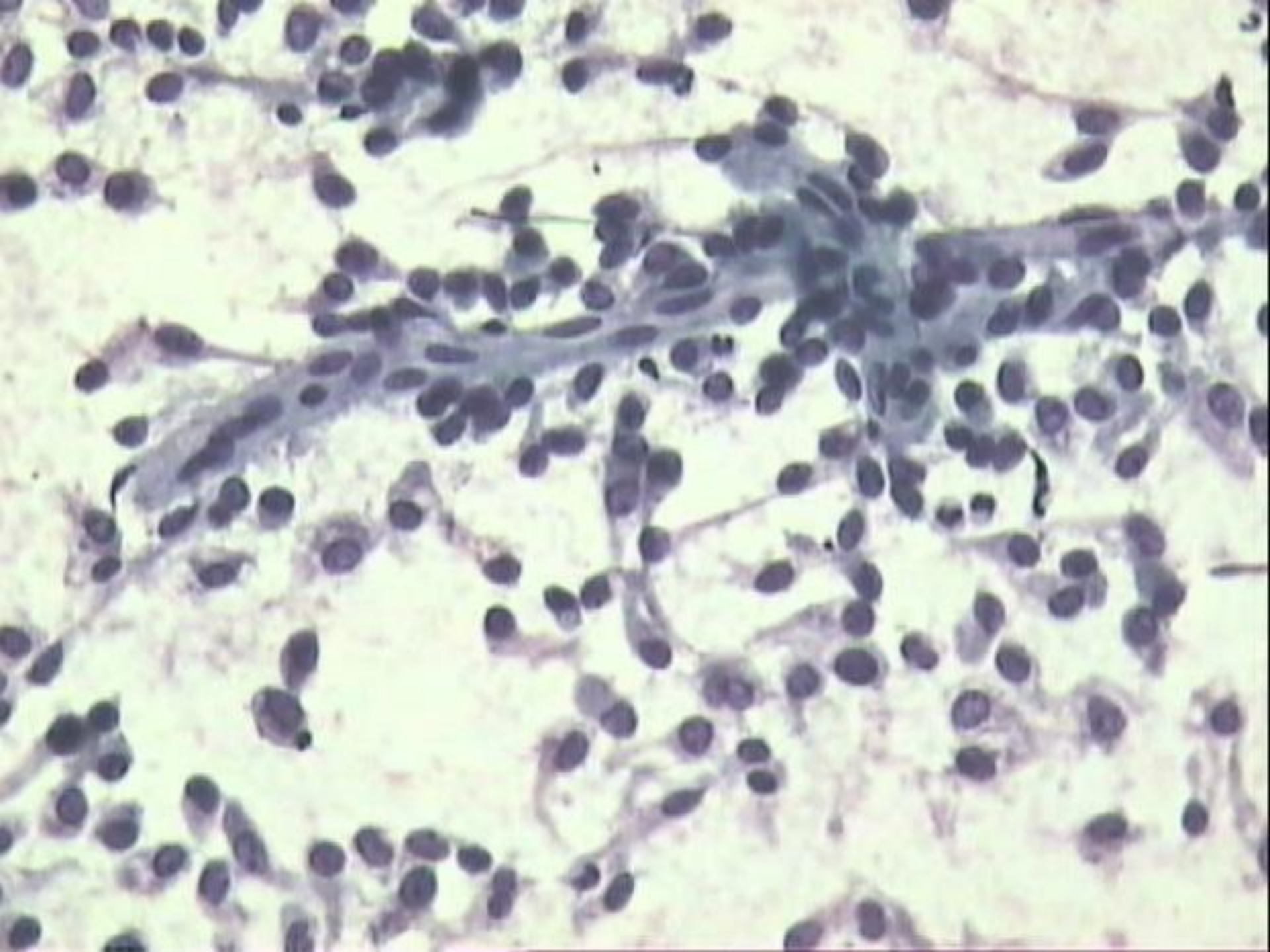

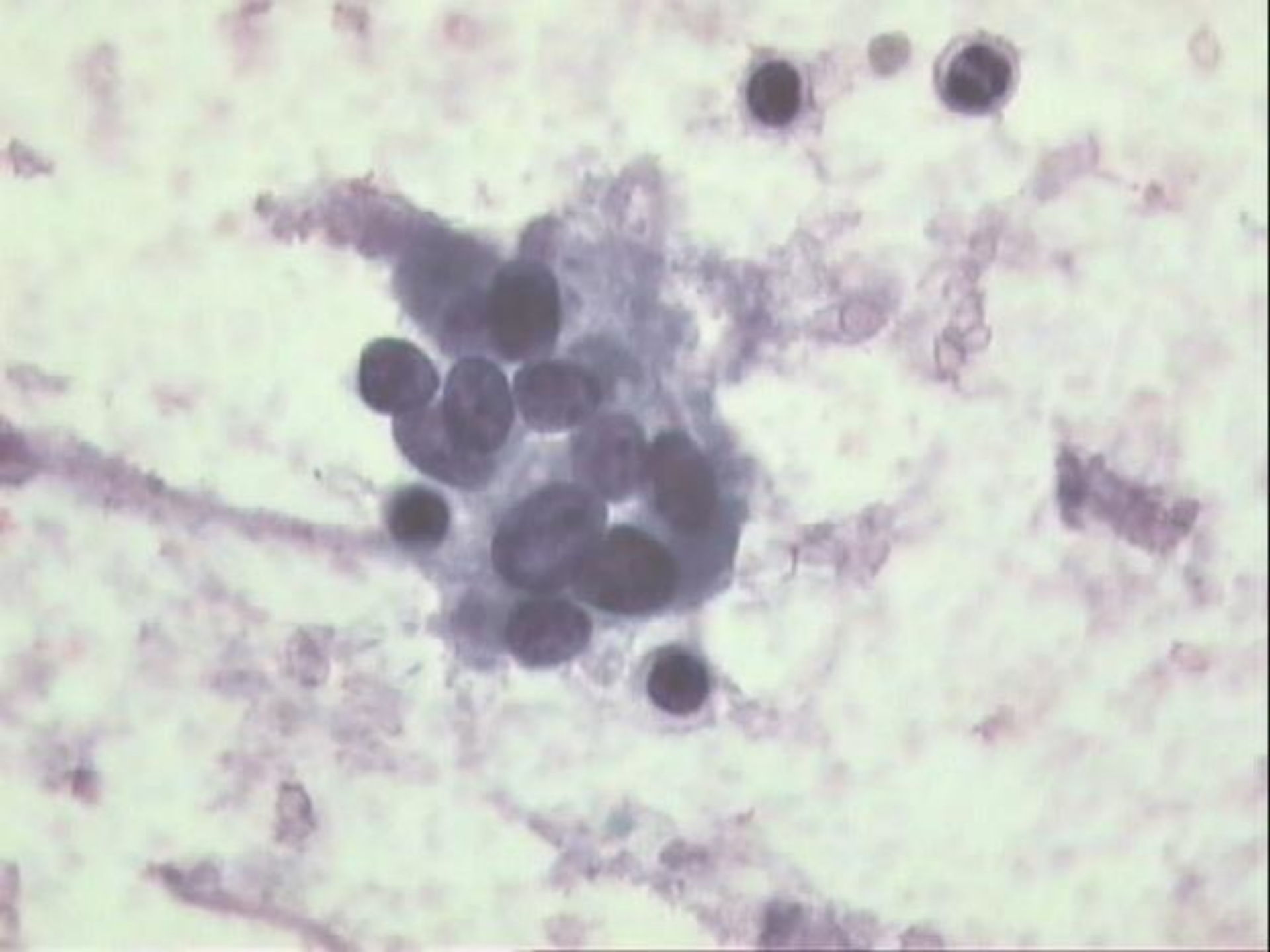

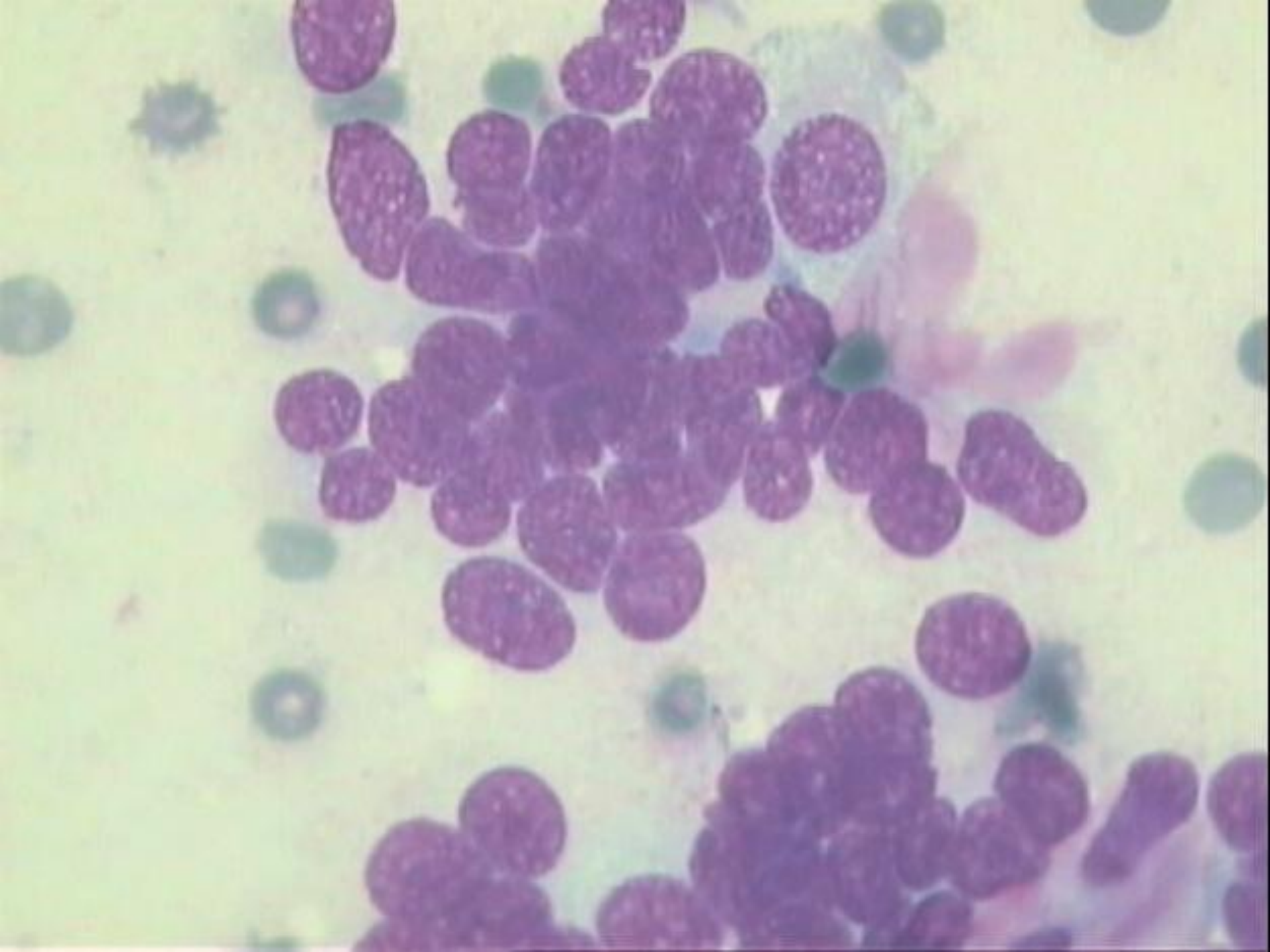

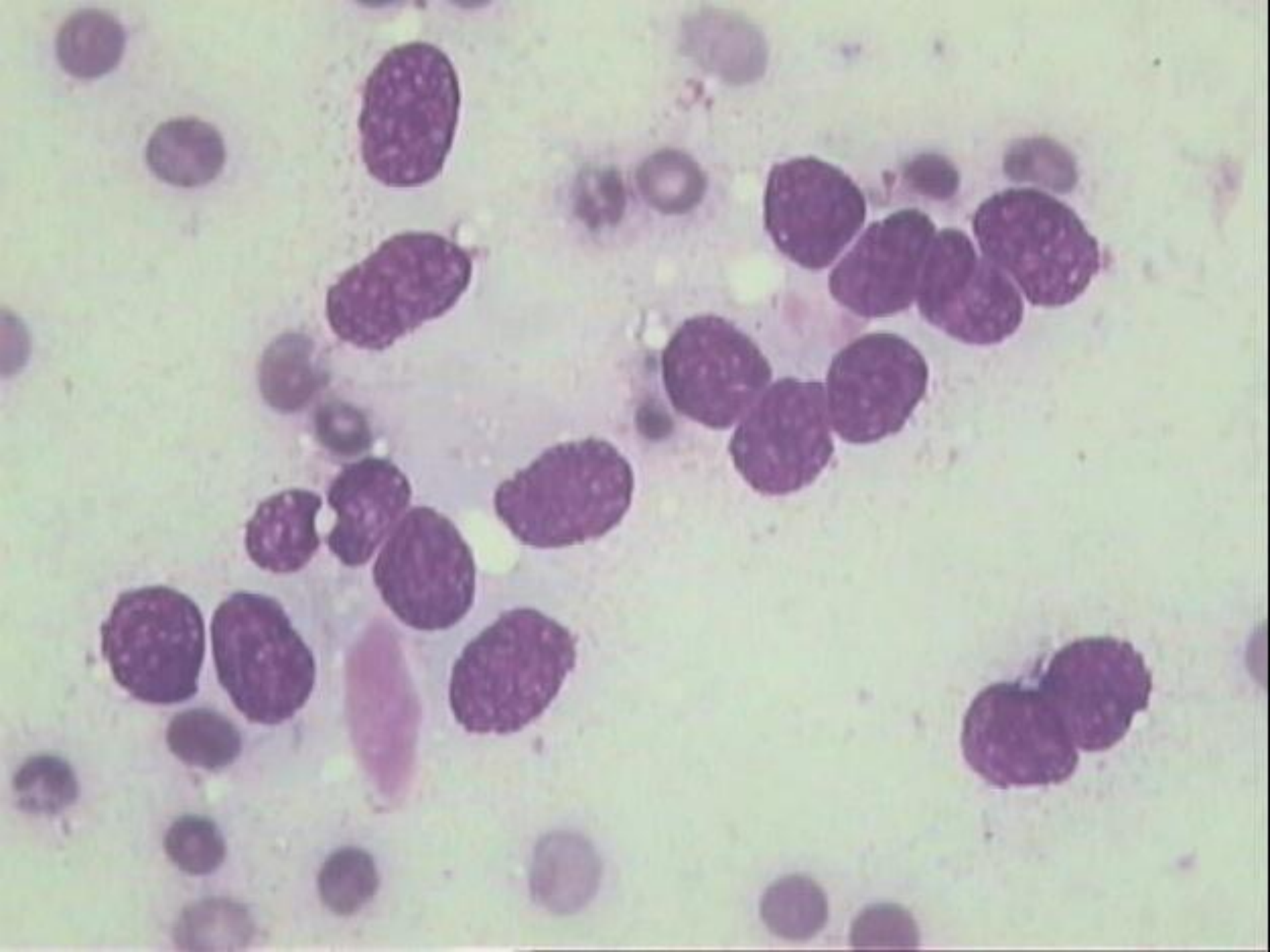

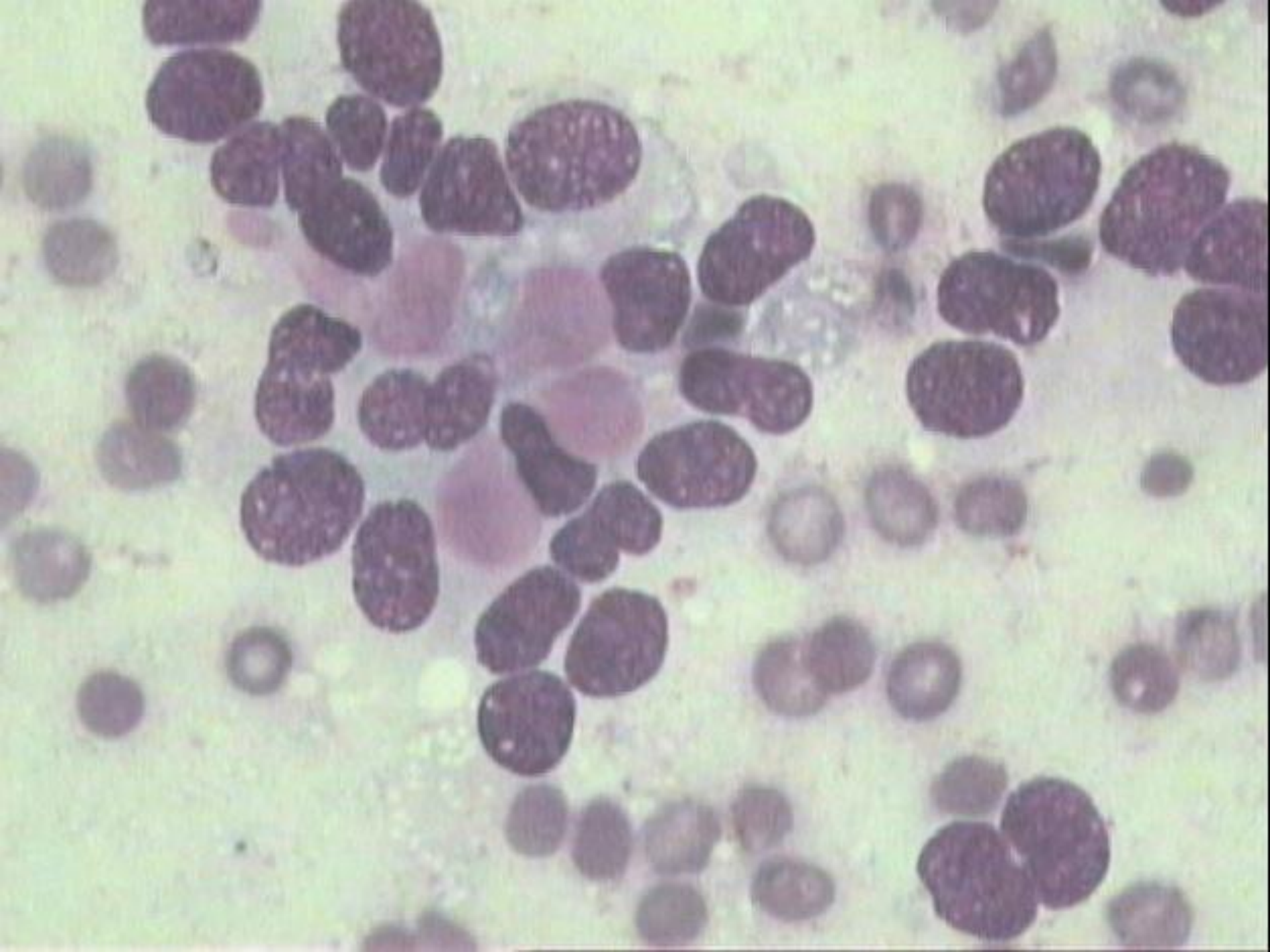

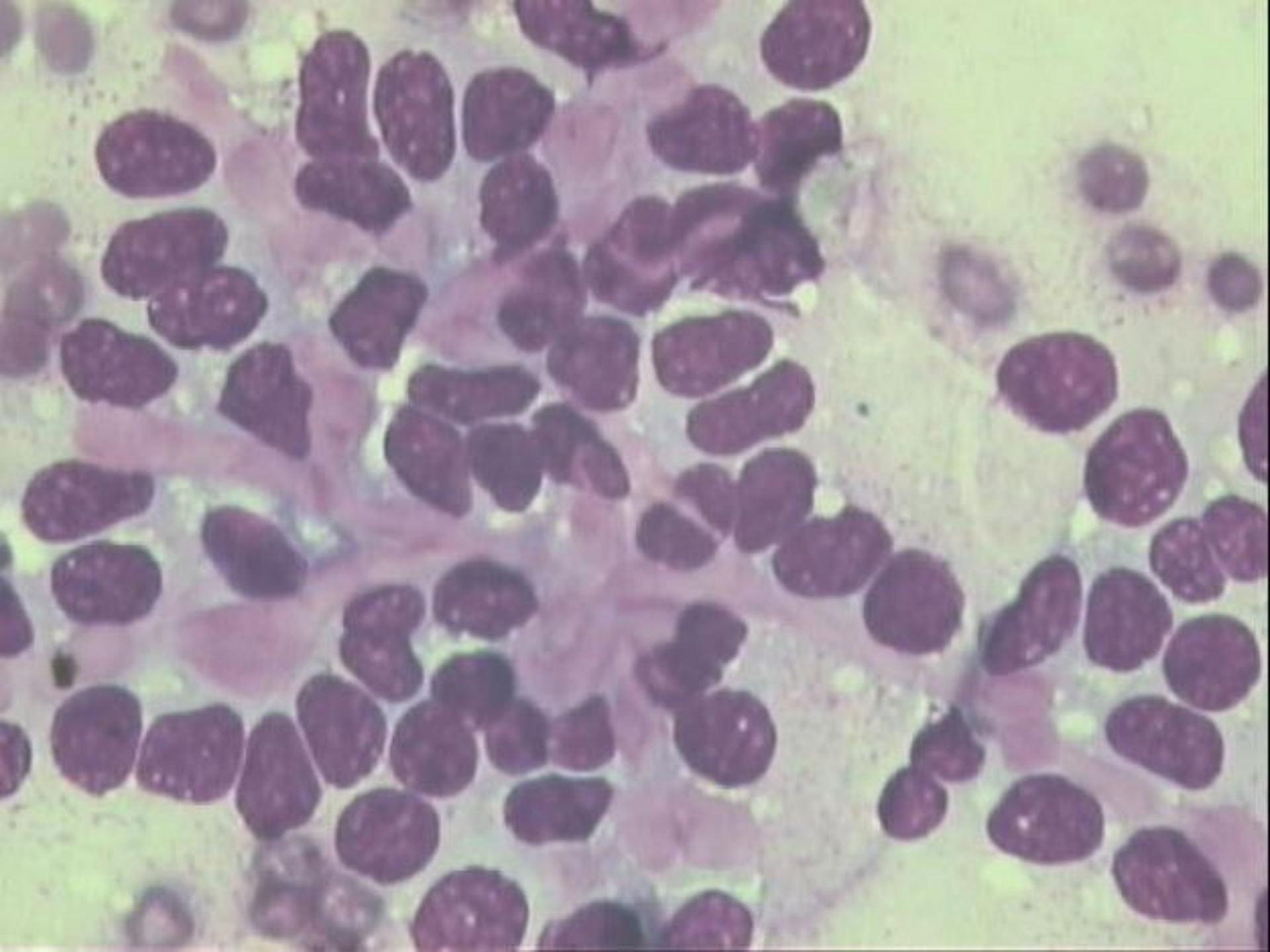

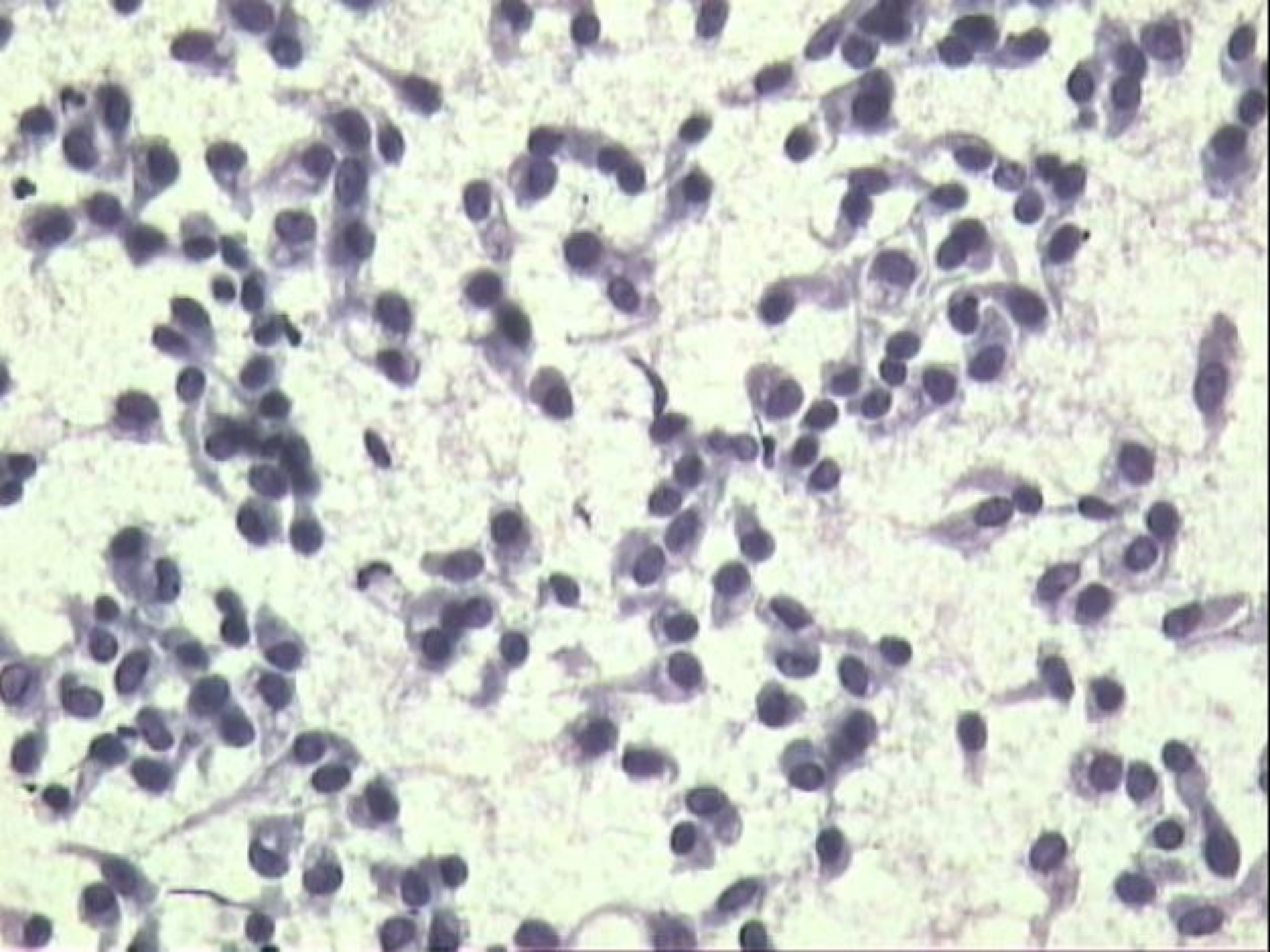

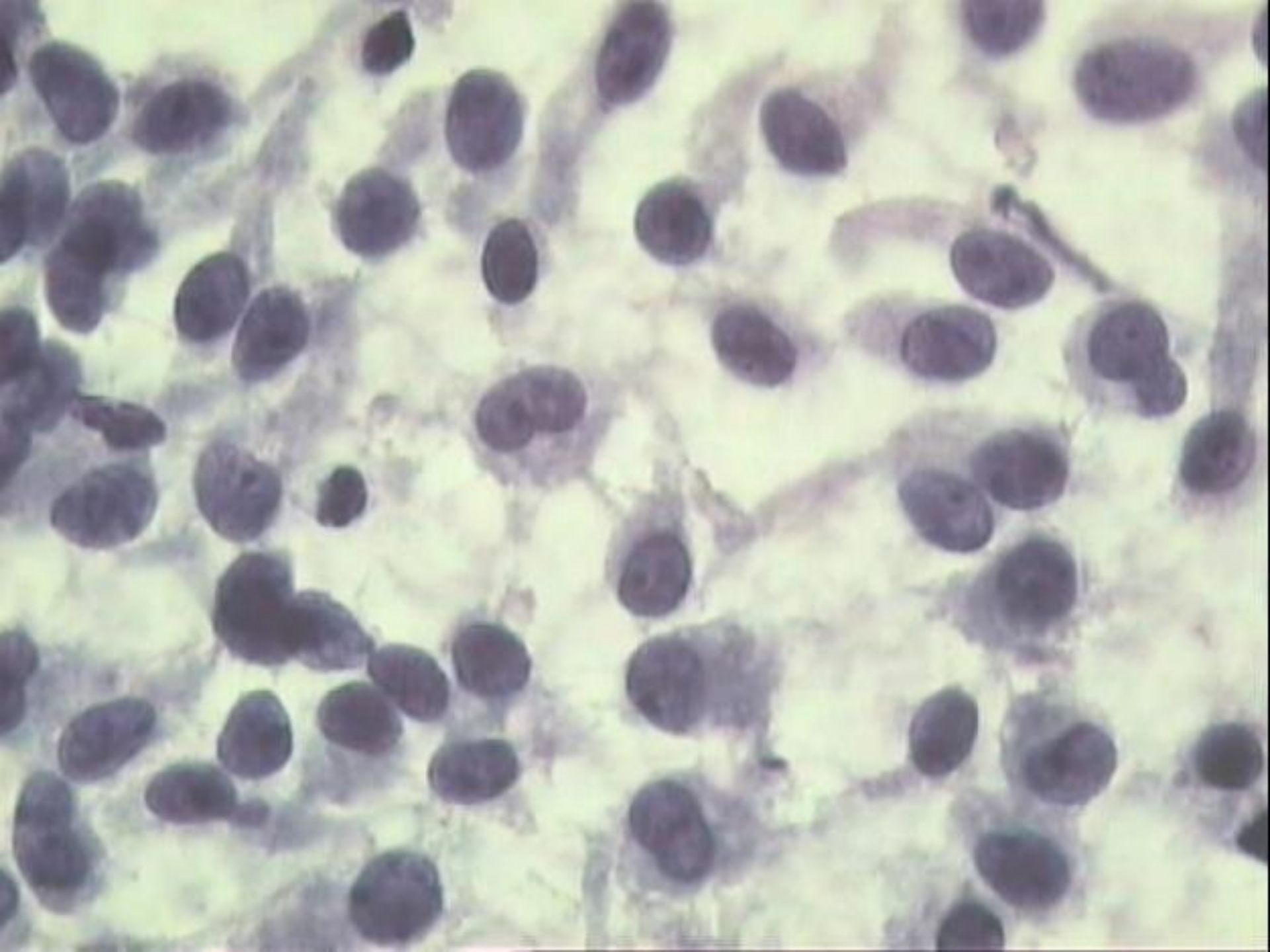

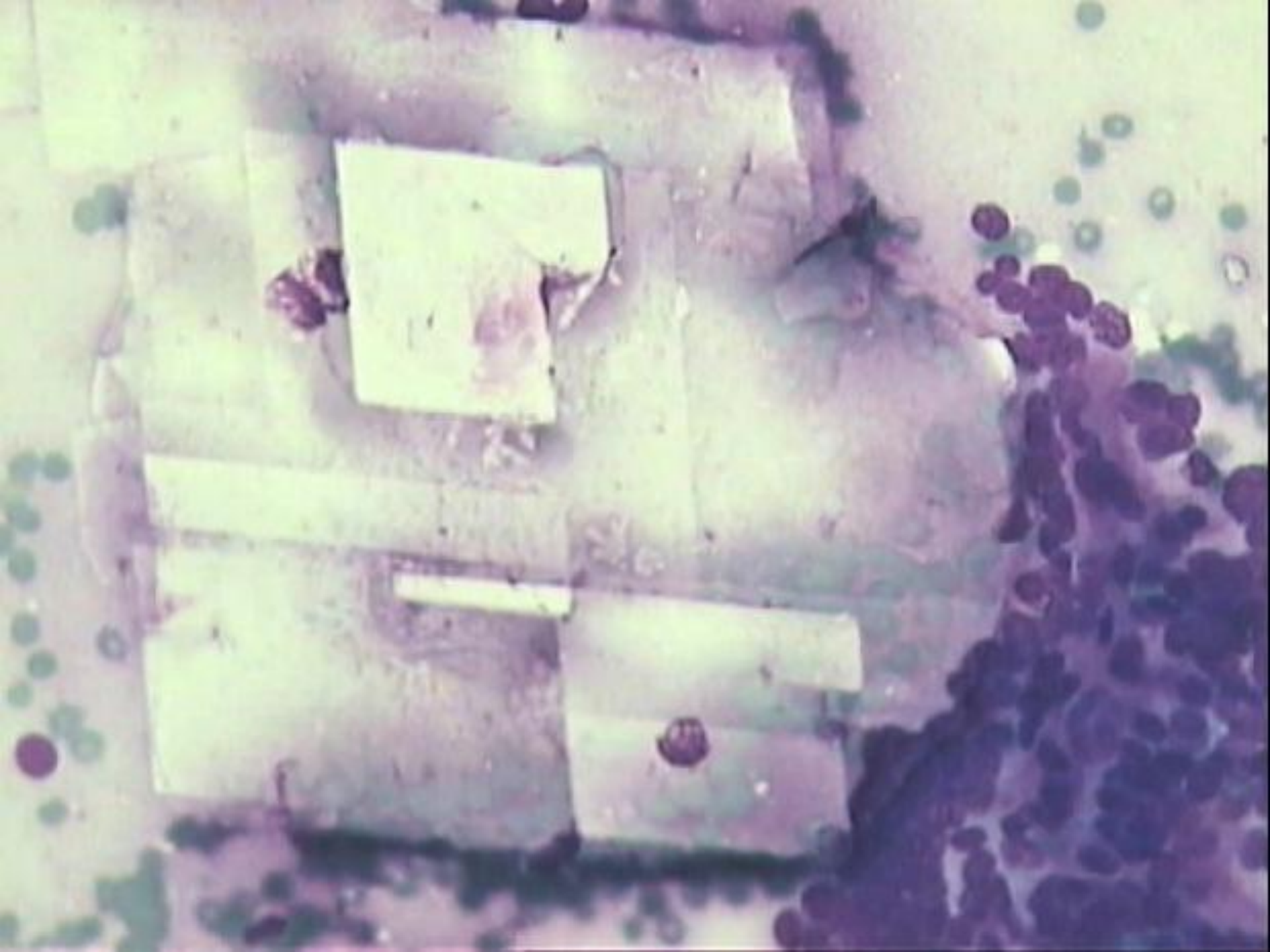

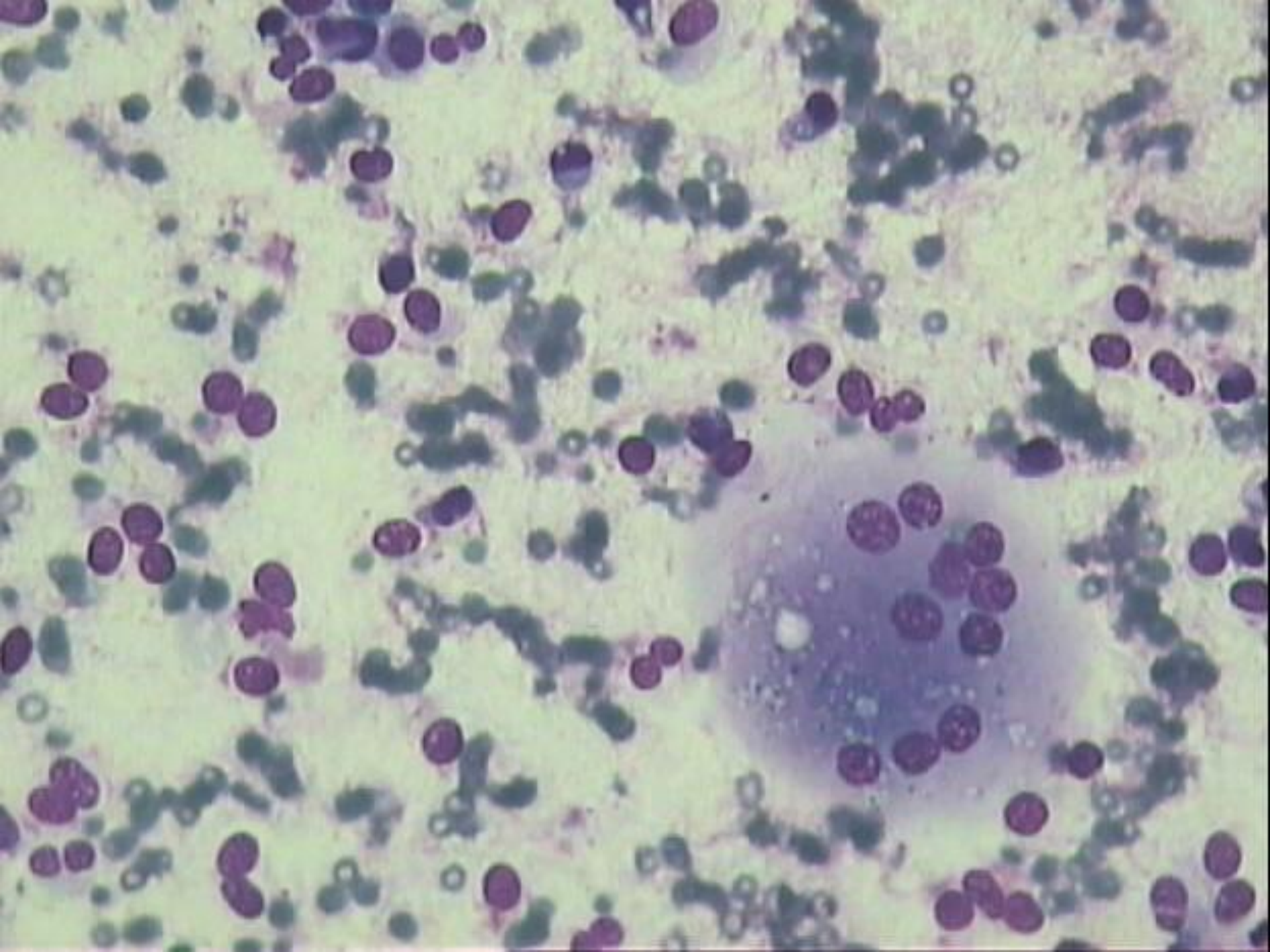

Diagnóstico:

TUMOR SÓLIDO PSEUDOPAPILAR

Distintos Nombres:

- Tumor epitelial papilar
- Tumor quístico papilar
- Tumor papilar sólido y quístico
- Tumor sólido pseudopapilar (OMS 1996)

Diagnóstico diferencial:

- Tumores mucinosos
- Adenoma microquístico.
- Tumores endocrinos.

Solid-Pseudopapillary Tumor of the Pancreas:

A Neoplasm With Distinct and Highly Characteristic Cytological Features

Guido Pettinato, M.D.,[1*] Dolores Di Vizio, M.D.,[1] J. Carlos Manivel, M.D.,[2] Stefan E. Pambuccian, M.D.,[2] Pasquale Somma, M.D.,[1] and Luigi Insabato, M.D.[1]

The solid-pseudopapillary tumor of the pancreas (SPTP) is an unusual low-grade malignant epithelial tumor affecting predominantly adolescent girls and young women. Although approximately 500 cases of SPTP have been described in the last 40 yr, its pathogenesis remains uncertain. However, the clinical features of this neoplasm are very characteristic and SPTP must be suspected in any young woman with a cystic or partially cystic pancreatic mass. In this report, we describe the cytologic features of seven cases of SPTP investigated by preoperative fine-needle aspirates. The analysis of the cytologic features in these cases and in 43 cases collected from the literature reveals that they are highly characteristic and quite distinct from those of other cystic or solid tumors of the pancreas. On this basis, a cytologic diagnosis of SPTP may be rendered with great confidence, not only in clinically typical examples, but also in unusual presentations, such as in older patients, in males, in ectopic locations, and in metastatic sites. Diagn. Cytopathol. 2002;27:325–334.

© 2002 Wiley-Liss, Inc.

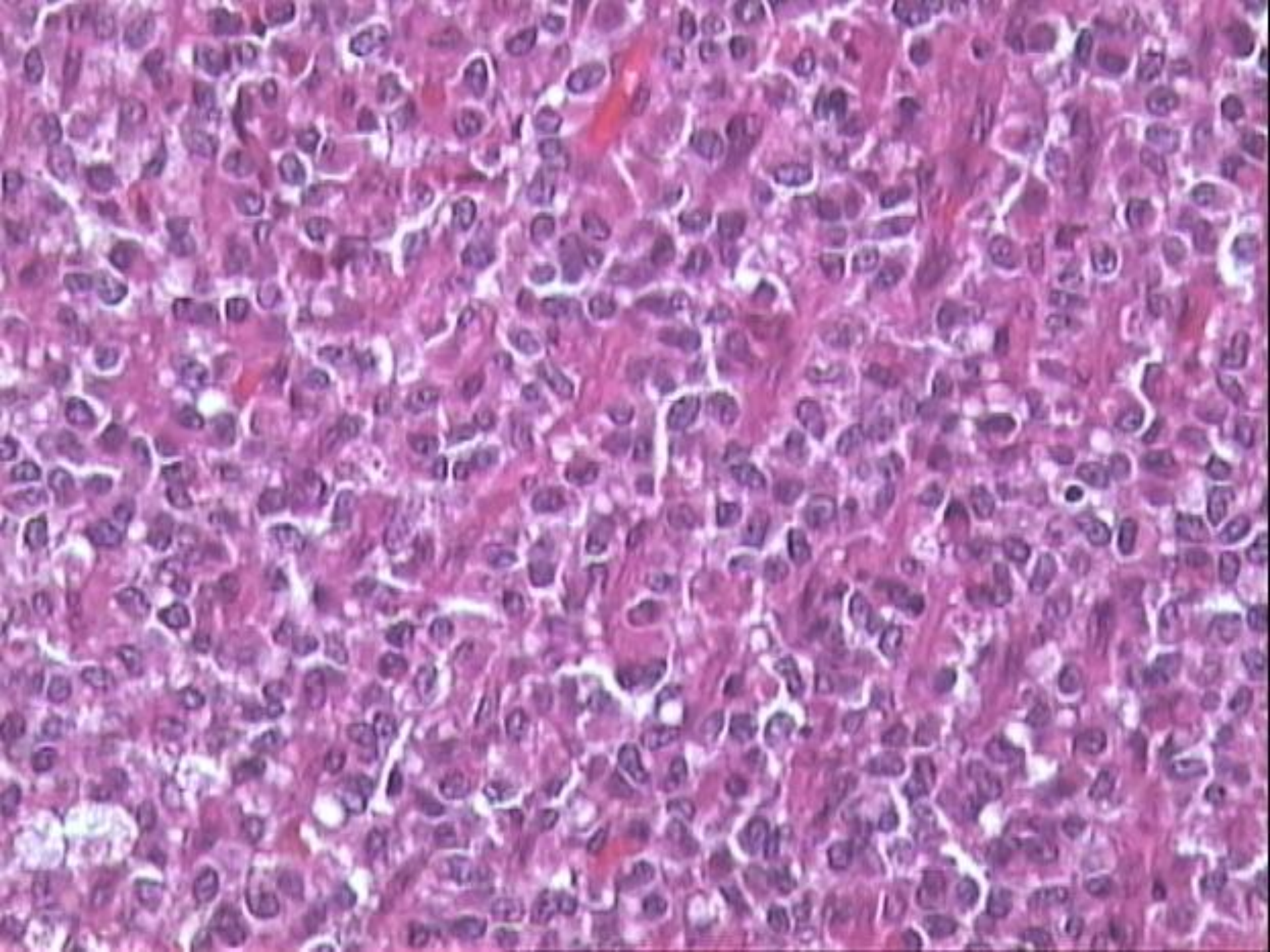

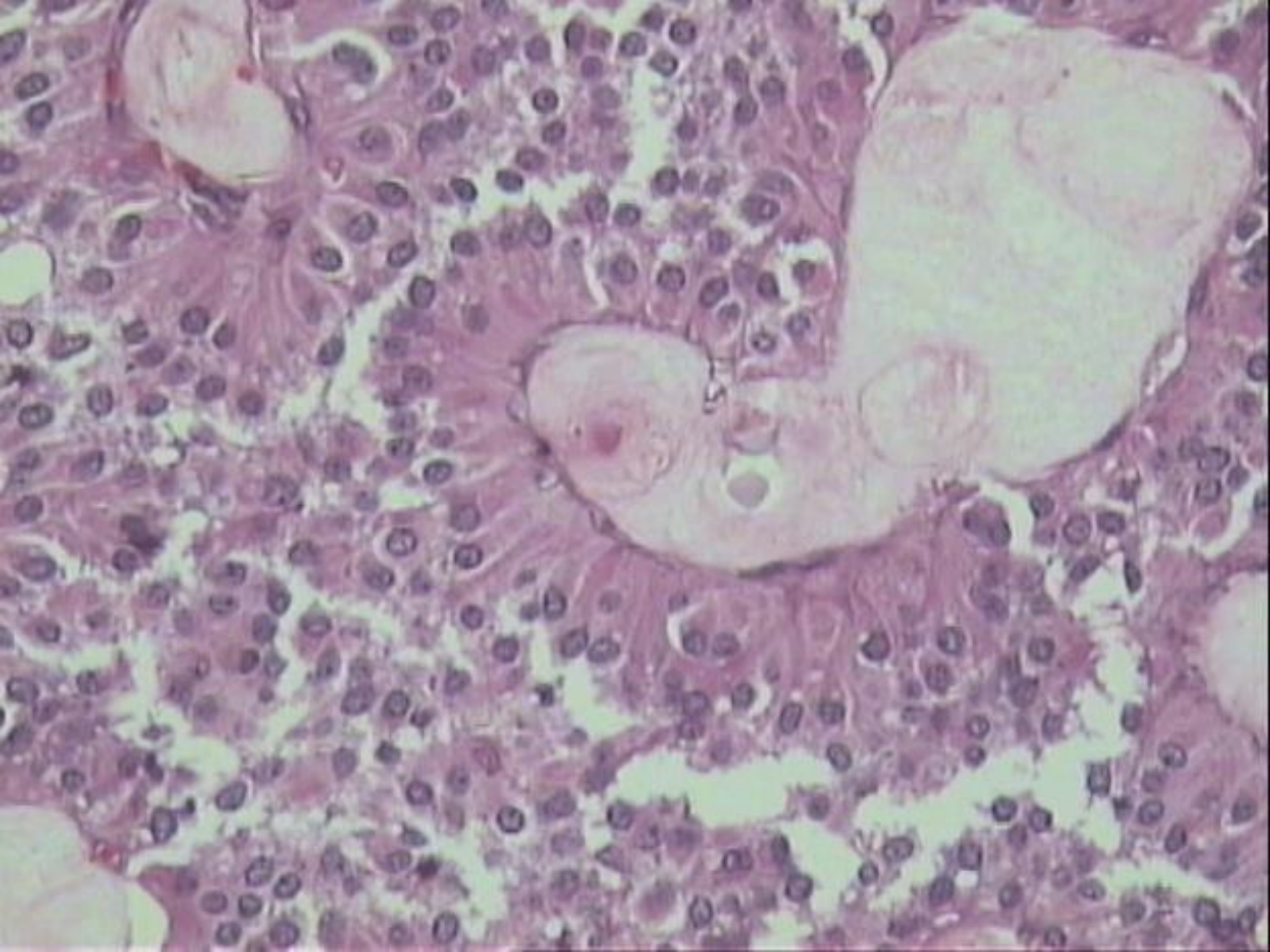

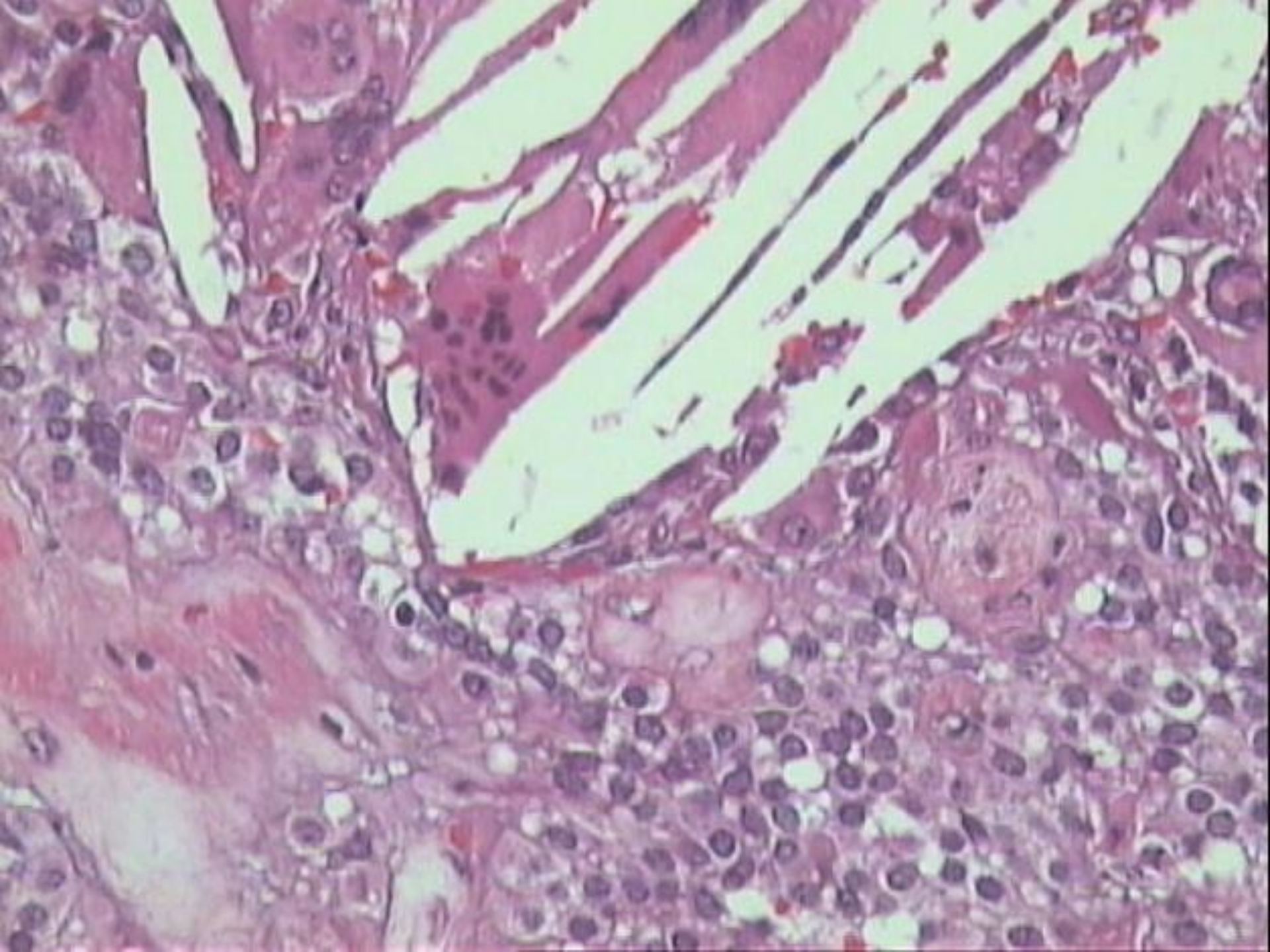

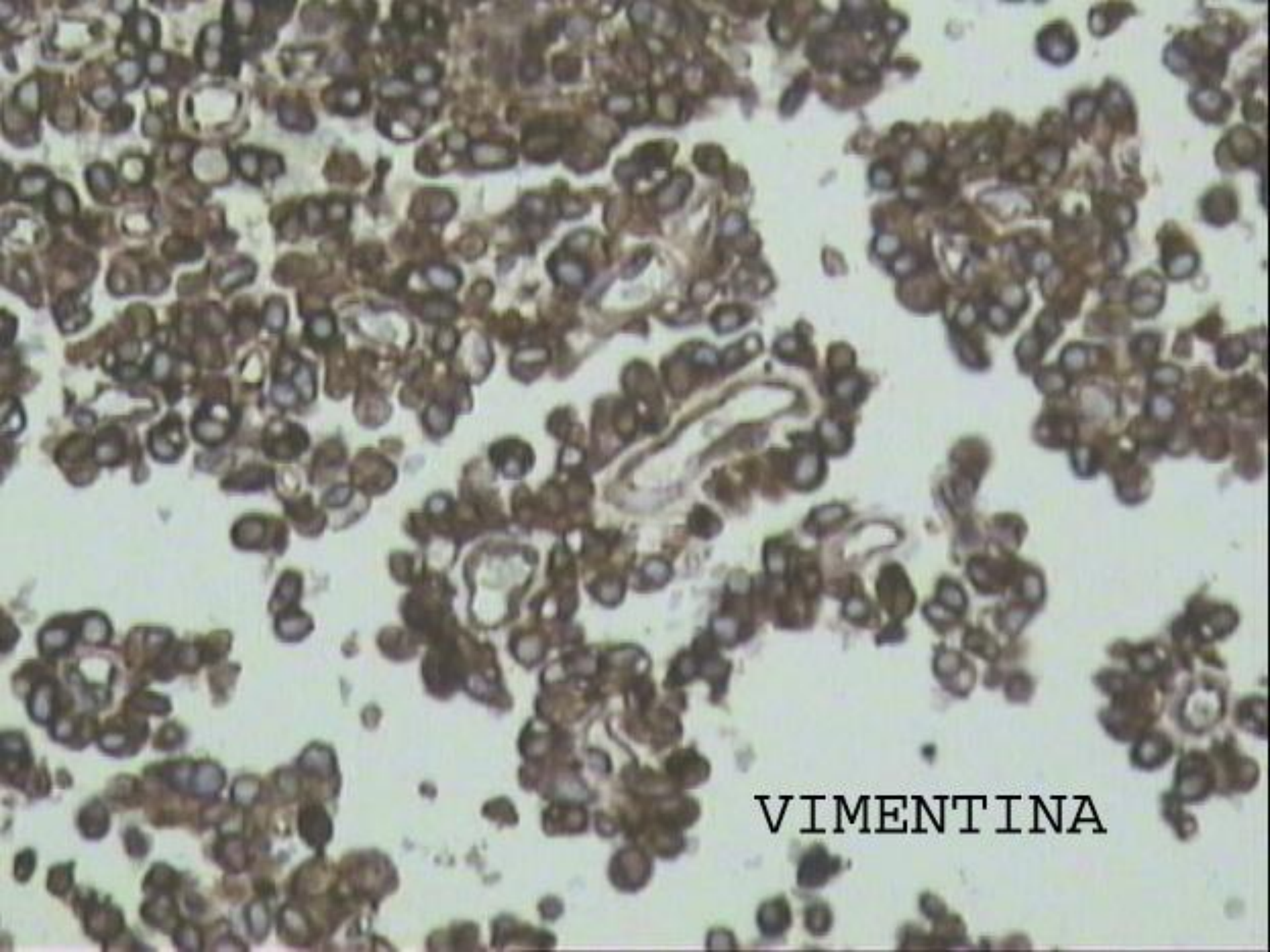
VIMENTINA

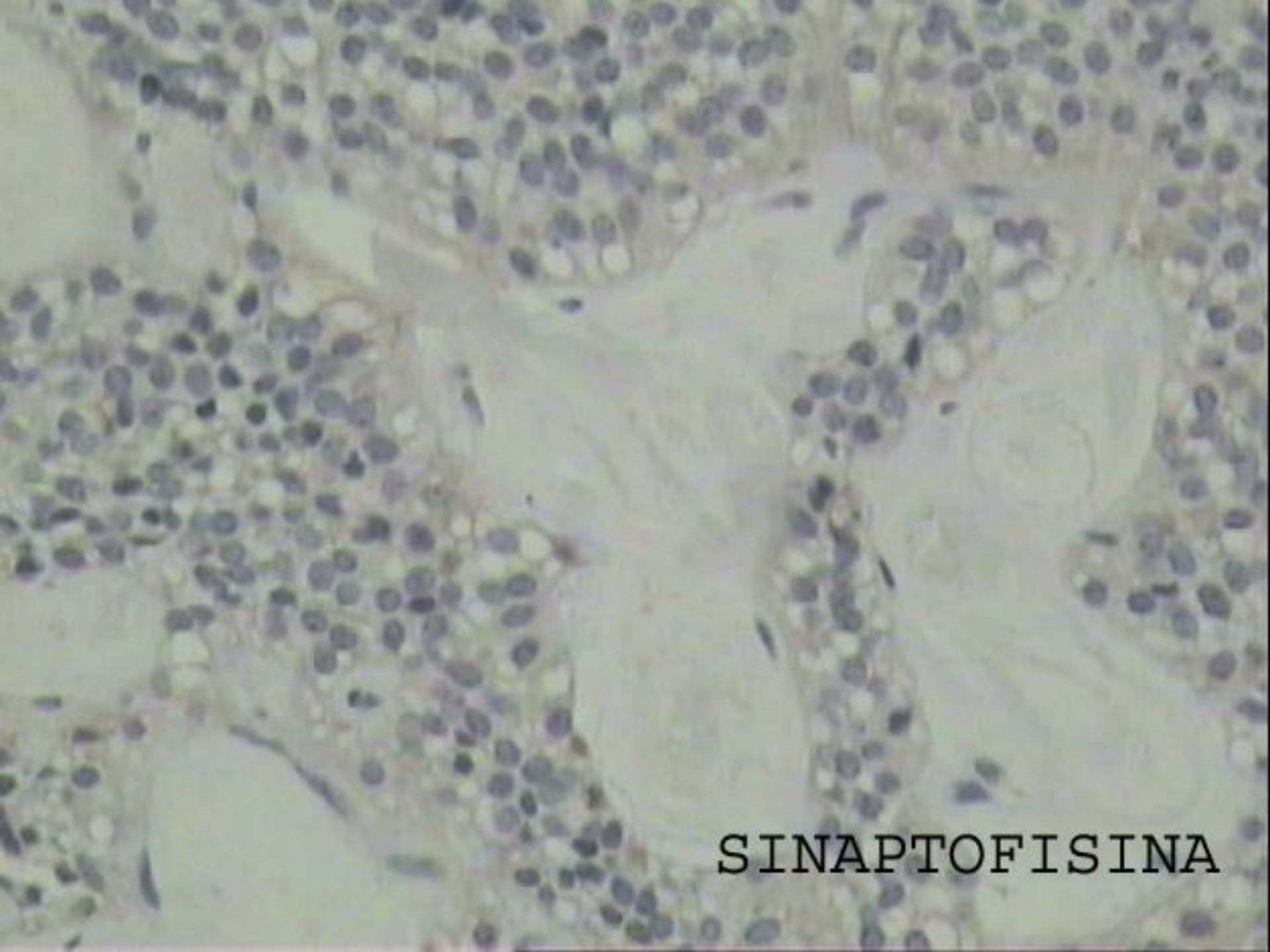
SINAPTOFISINA

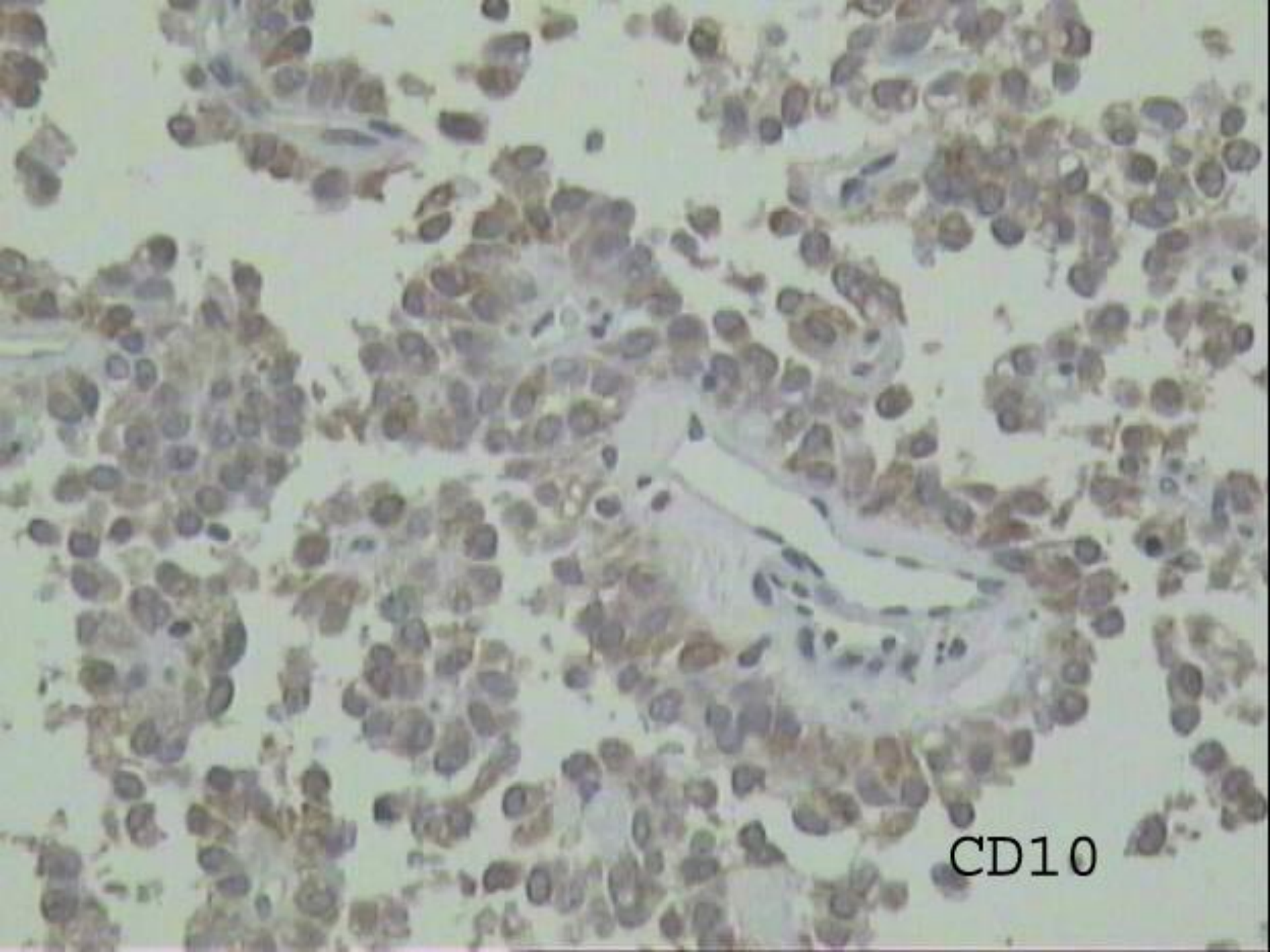
CD10

Características:

- Predominio en mujeres jóvenes
- Raro (1-2% de tumores no endocrinos)
- Localizado en cuerpo y cola preferentemente
- Tumor de bajo potencial maligno (15% recidiva local y metástasis)

¡ DIAGNOSTICO PREOPERATORIO !

Permite un tratamiento quirúrgico curativo.