CASO 9

85 REUNIÓN DE LA ASOCIACIÓN TERRITORIAL VALENCIANA DE LA SOCIEDAD ESPAÑOLA DE ANATOMIA PATOLOGICA

VINAROZ, DICIEMBRE, 2003

- Varón de 58 años
- Marzo - 2003: masa hiliar pulmonar derecha:
  - DX citológico y biopsia: carcinoma broncopulmonar de célula pequeña
- TTO concomitante : RT-QT
- Octubre-2003 : 6°ciclo de QT
  - Broncoscopia de control: zona retraída en bronquio intermediario
  - Cepillado y biopsia de la lesión

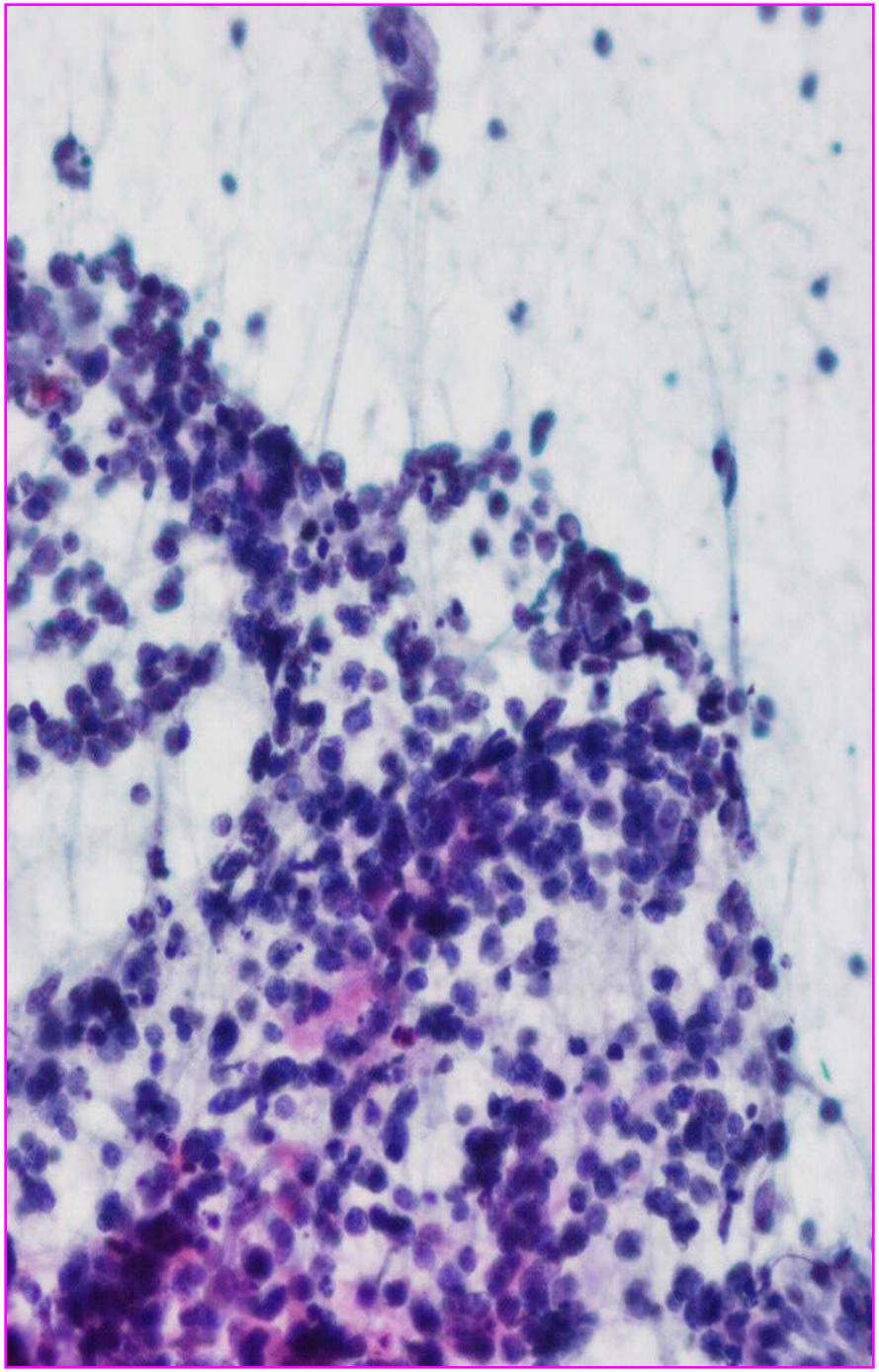

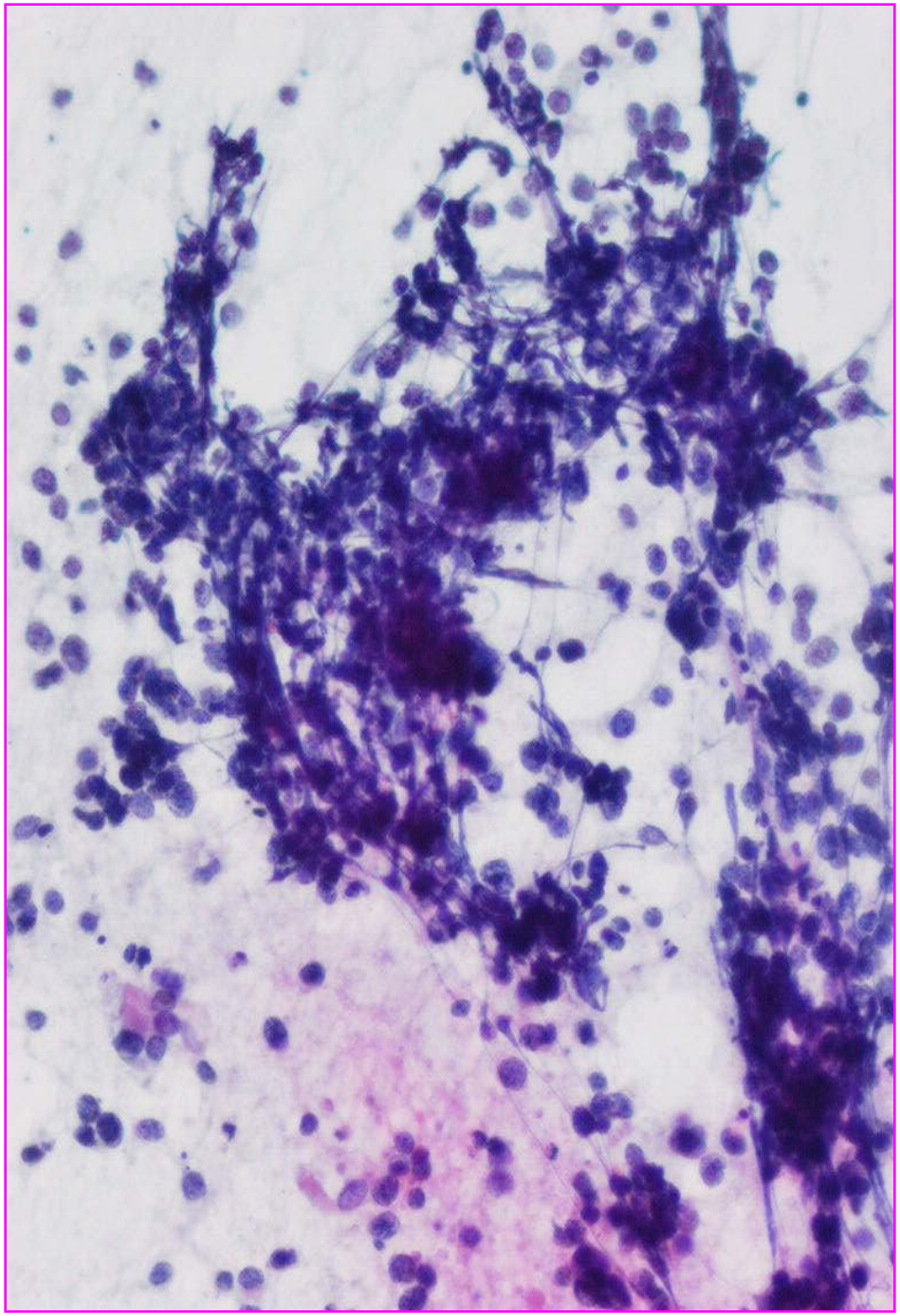

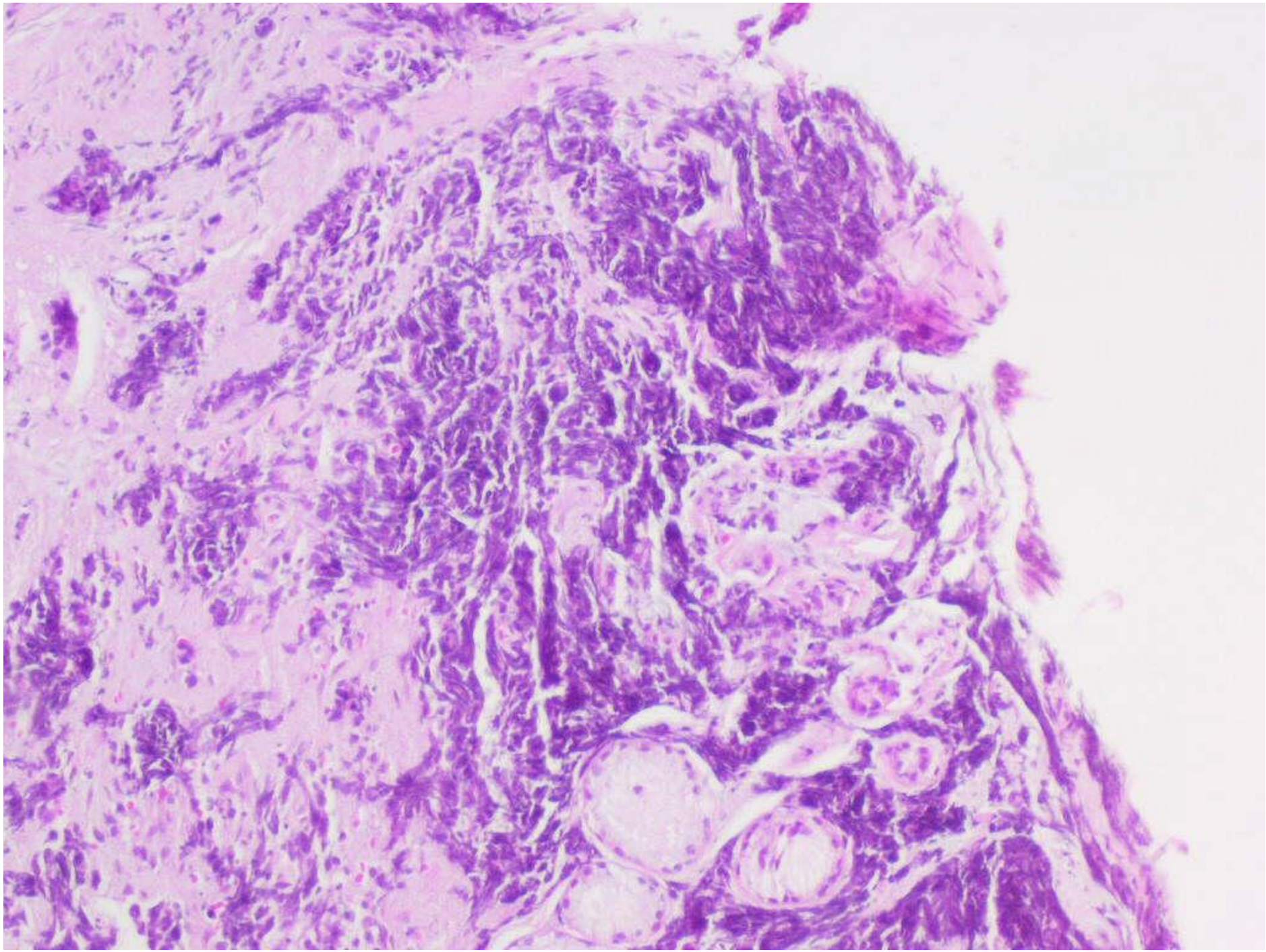

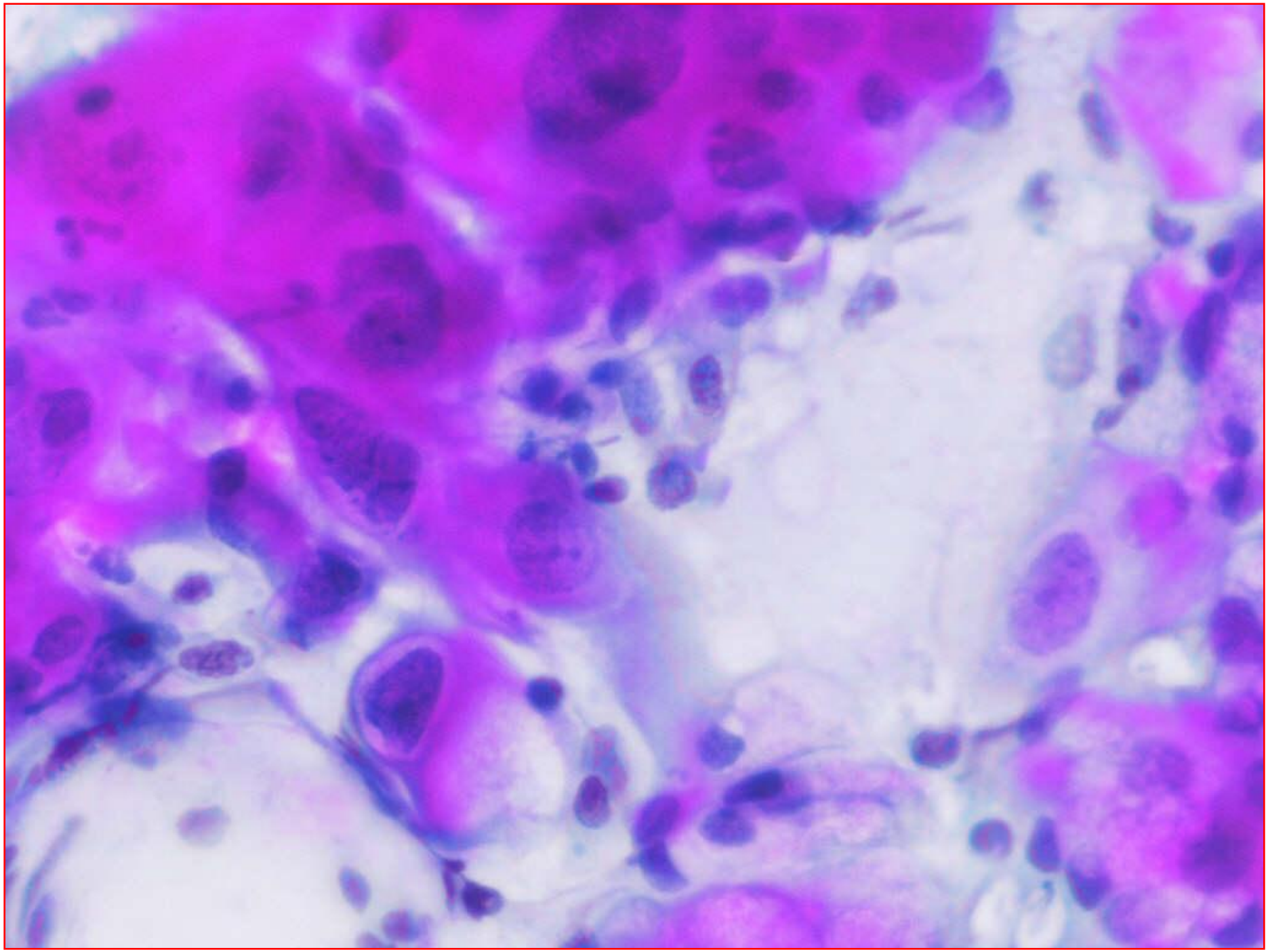

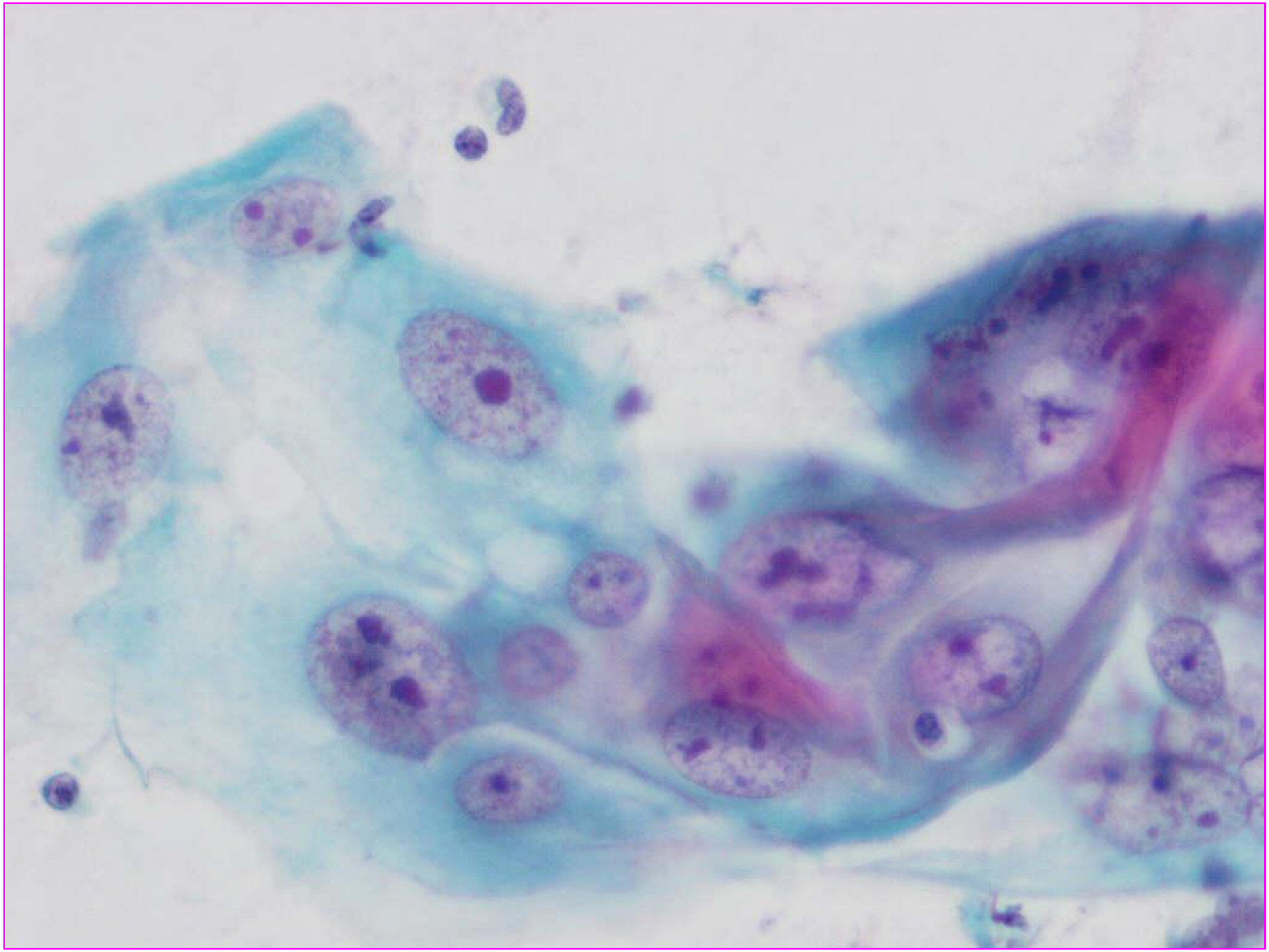

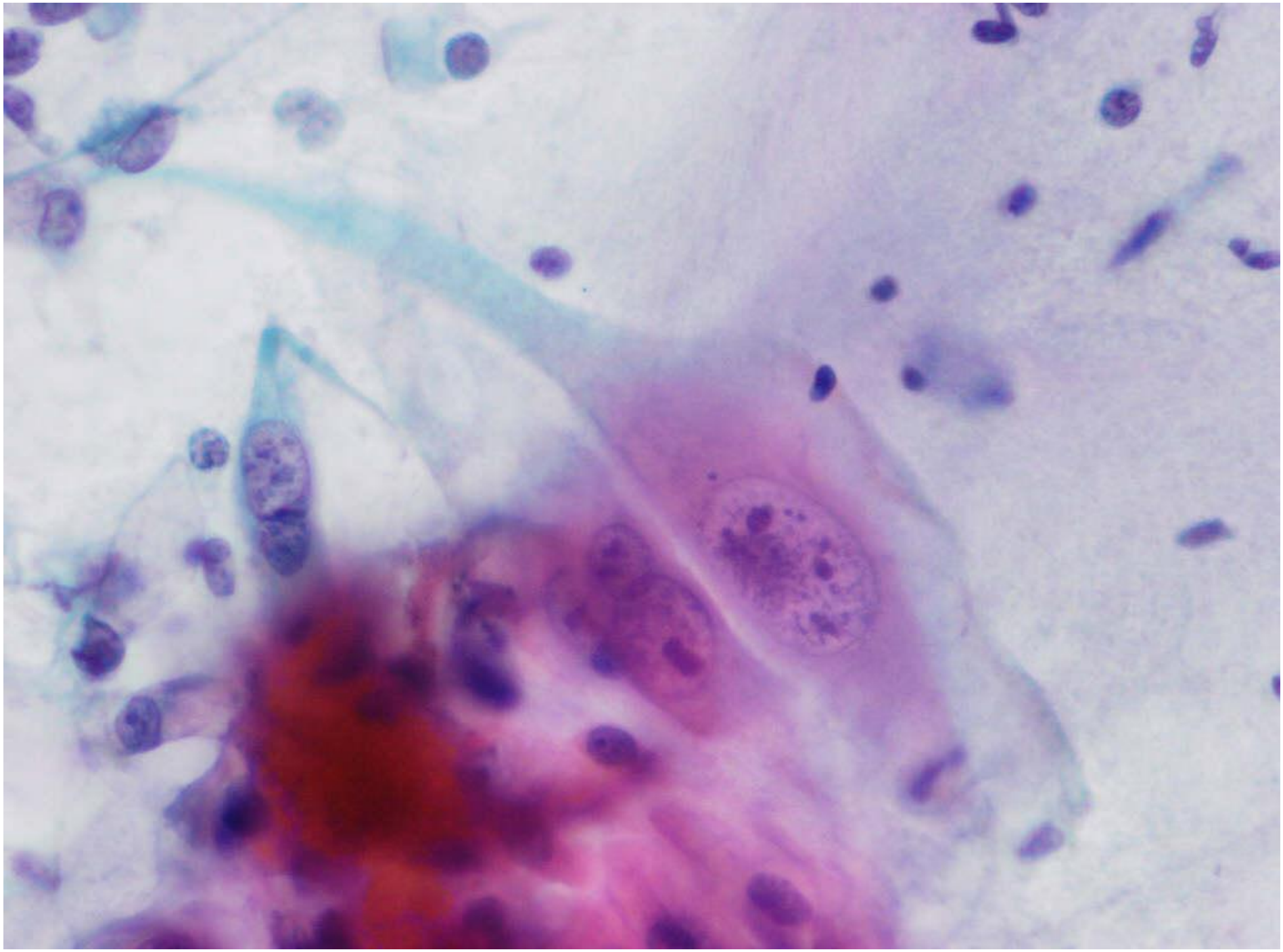

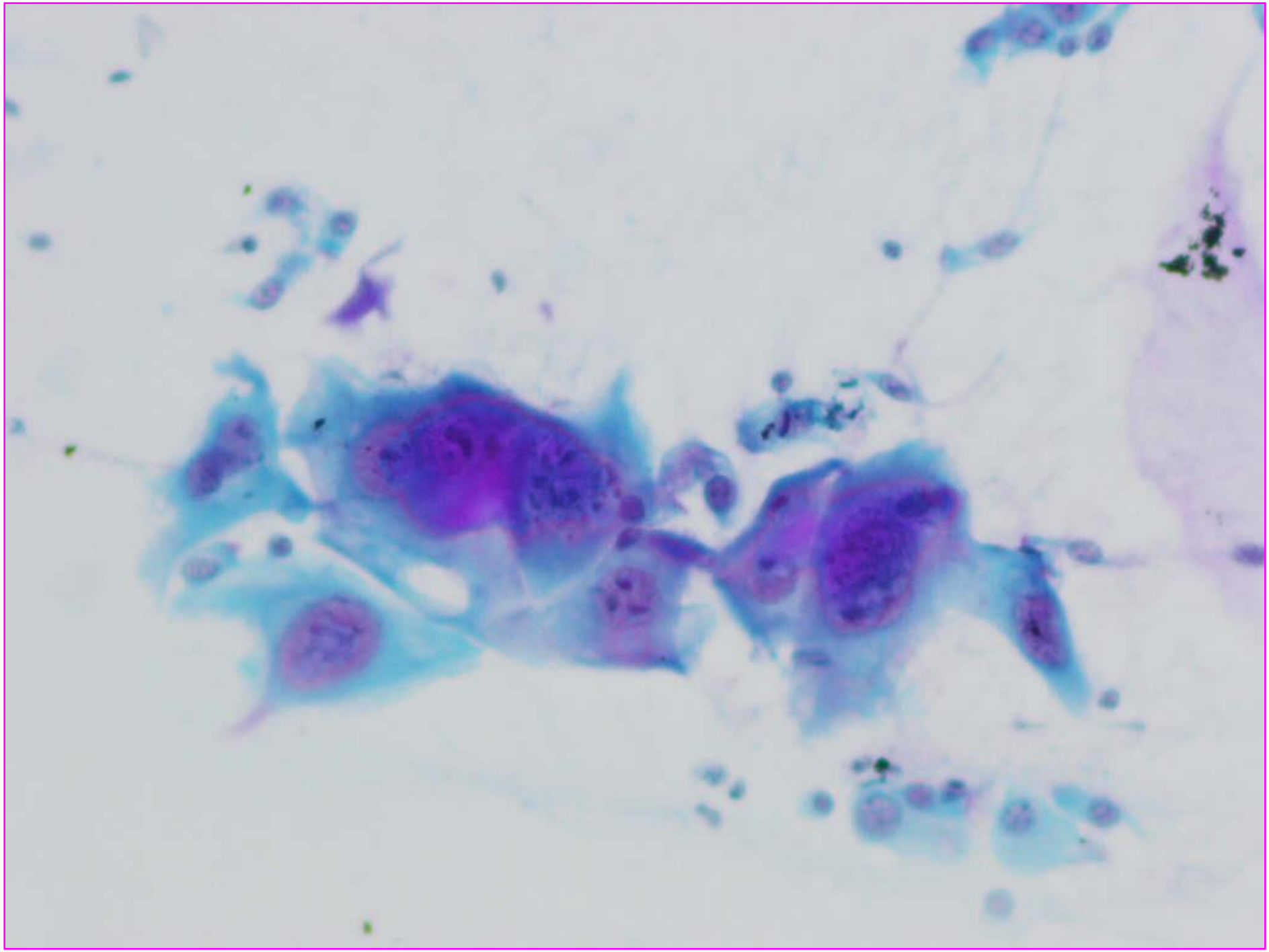

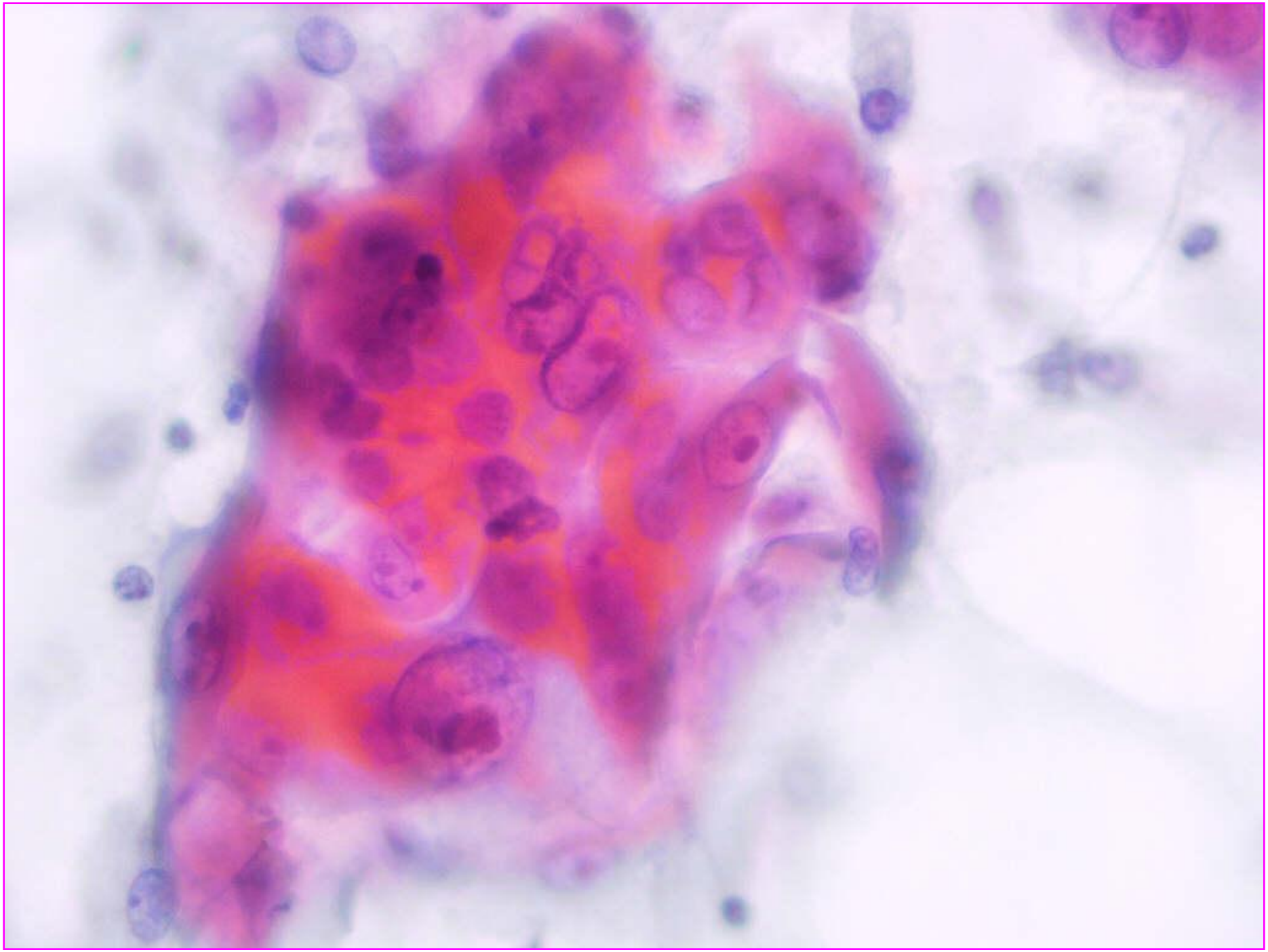

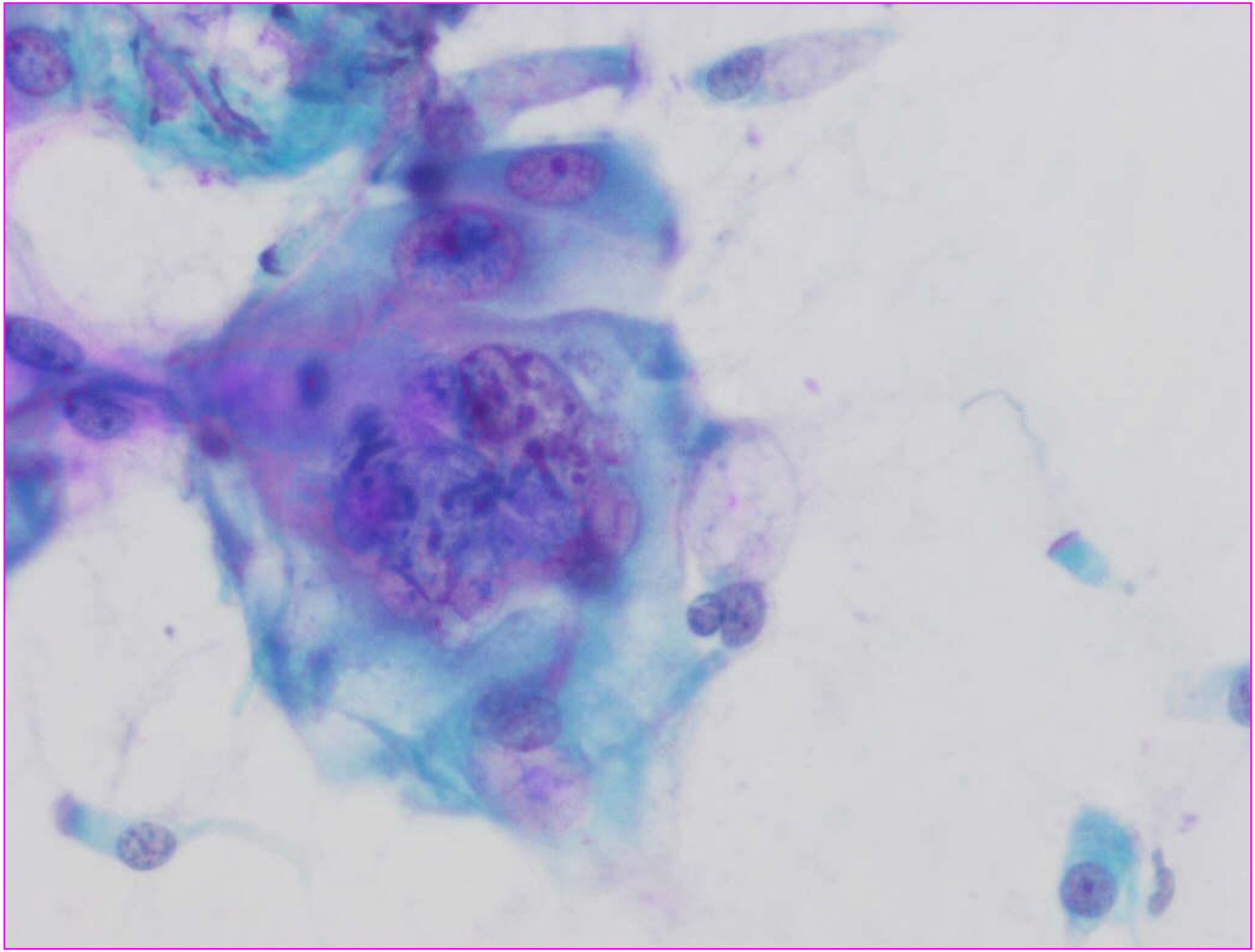

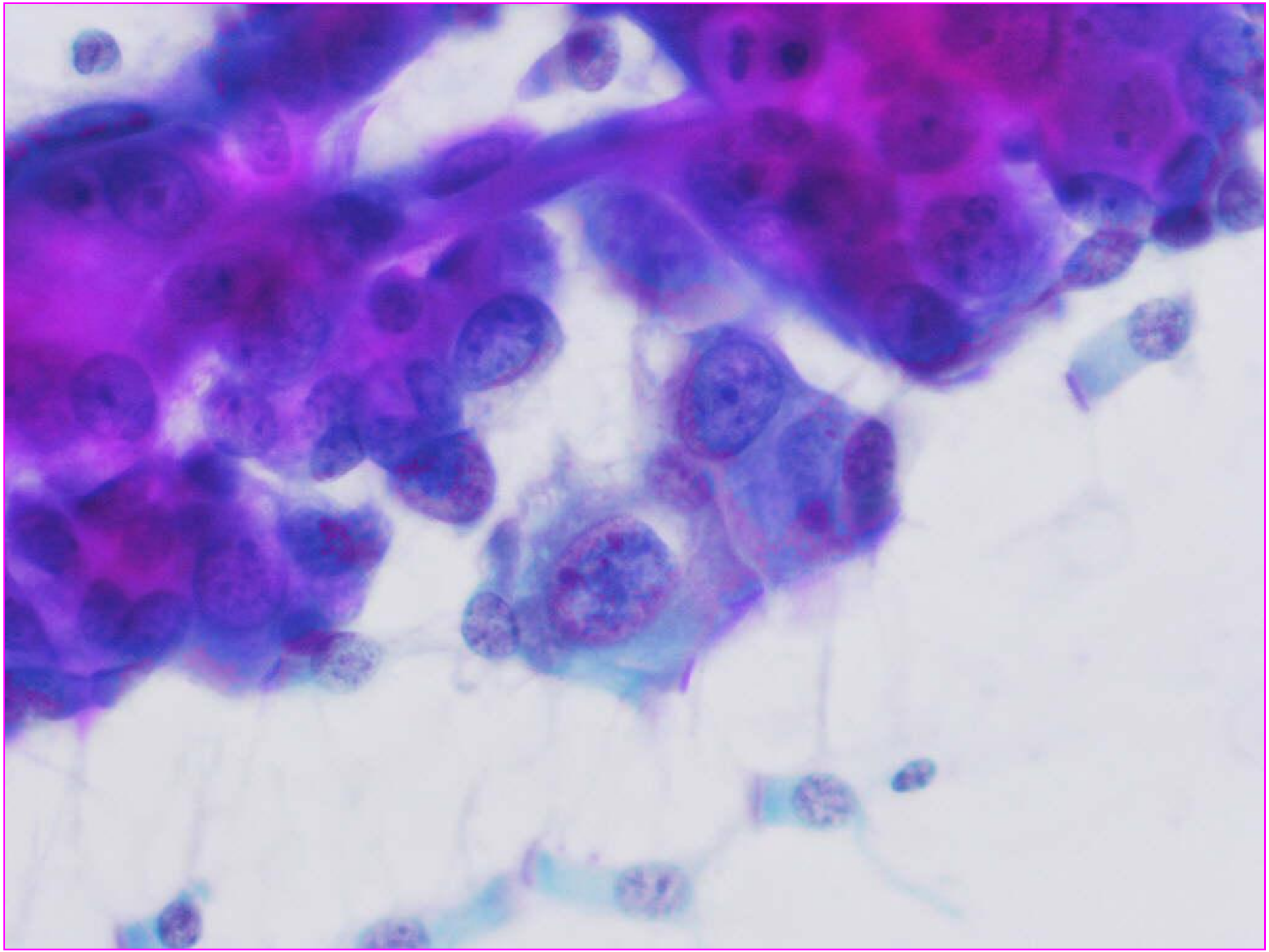

DIAGNÓSTICO

CAMBIOS CELULARES ASOCIADOS AL TRATAMIENTO (RT Y QT)

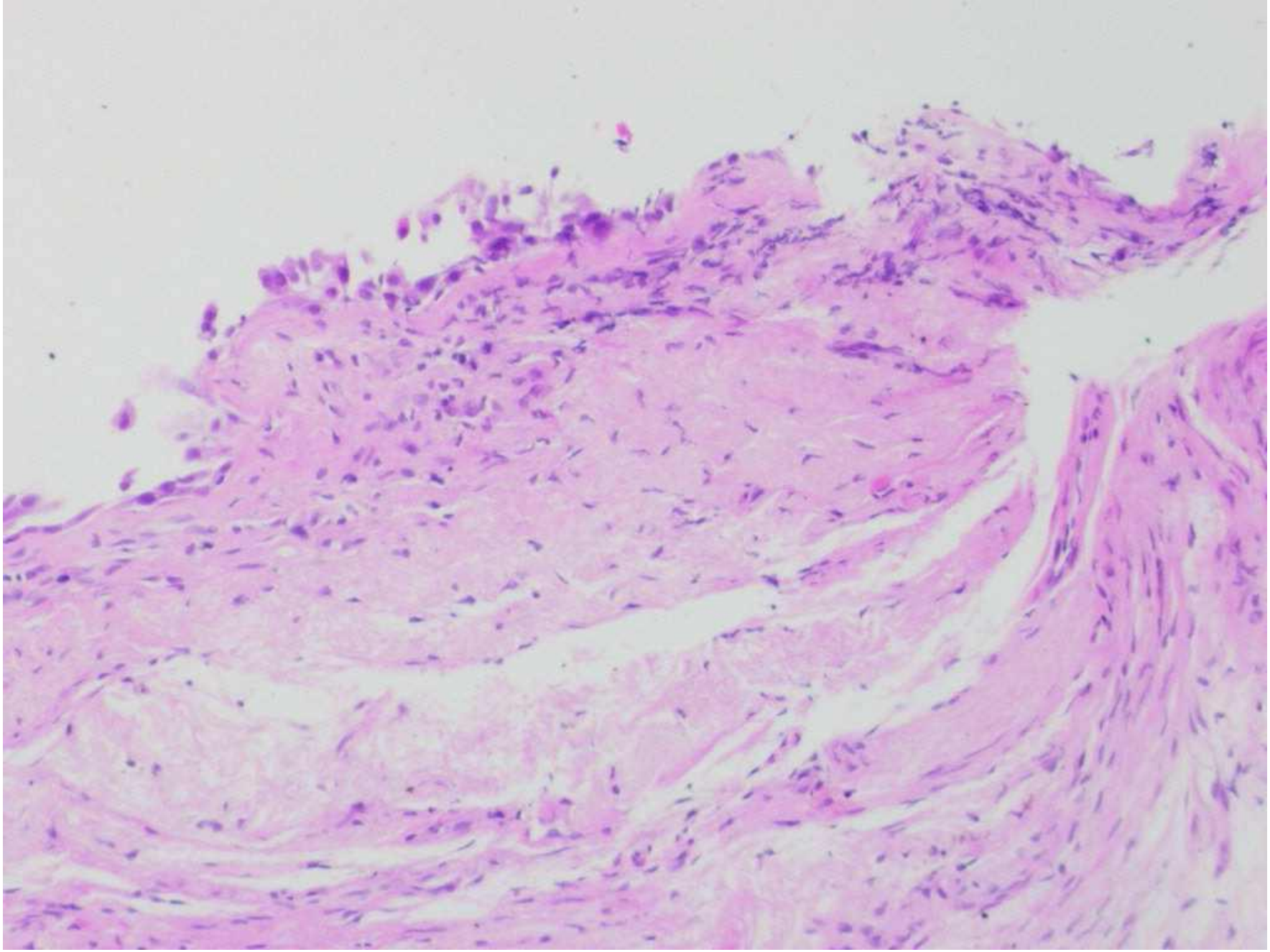

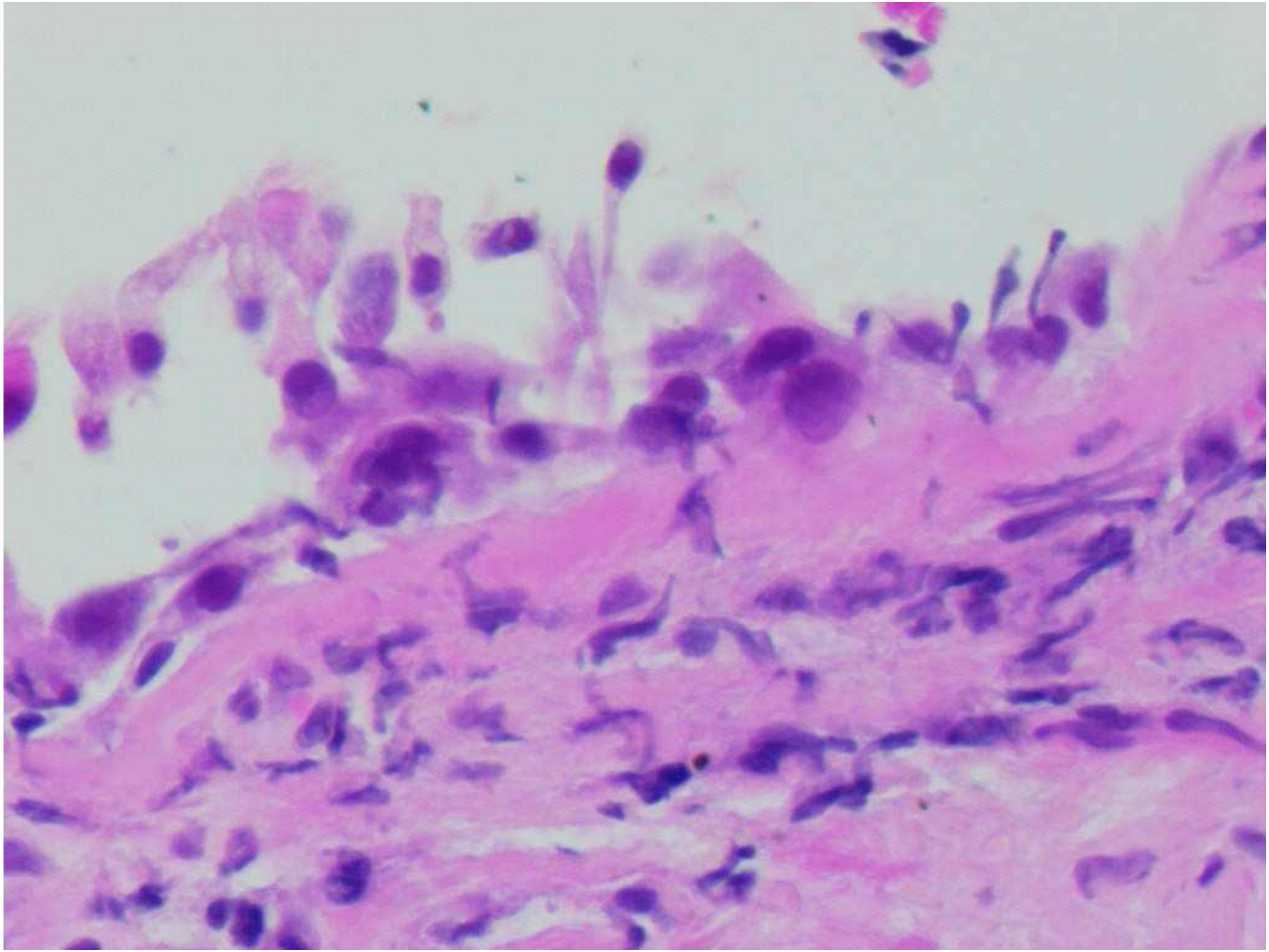

CAMBIOS ASOCIADOS A RT Y QT:

Criterios citológicos diagnósticos:

Aumento del tamaño celular:

- Aumento nuclear
  - Hipercromatismo: cromatina "borrosa" (poco definida)
  - Presencia de nucleolo
  - Multinucleación
- Aumento del tamaño citoplasmático
  - Prolongaciones citoplasmáticas
  - Vacuolización citoplasmática
  - **Se mantiene o está ligeramente aumentada, la relación núcleo/citoplasma**

Atkinson. Silverman. Atlas de dificultades diagnósticas en citopatología